

Standards and datasets for reporting cancers

Dataset for histopathological reporting of cervical neoplasia

March 2021

Authors: Dr Raji Ganesan, Birmingham Women's and Children's NHS Foundation Trust, Birmingham
Dr Naveena Singh, Barts Health NHS Trust, London
Dr Anthony T Williams, Birmingham Women's and Children's NHS Foundation Trust

Unique document number	G071
Document name	Dataset for histopathological reporting of cervical neoplasia
Version number	4
Produced by	Dr Raji Ganesan (Birmingham Women's and Children's NHS Trust), Dr Naveena Singh (Barts Health NHS Trust) and Dr Anthony T Williams (Birmingham Women's and Children's NHS Trust) on behalf of the College's Working Group on Cancer Services.
Date active	March 2021 (to be implemented within three months)
Date for review	March 2024
Comments	This document replaces the 3rd edition of <i>Dataset for histological reporting of cervical neoplasia</i> , published in 2011. In accordance with the College's pre-publications policy, this document was on the Royal College of Pathologists' website for consultation from 29 September to 27 October 2020. Responses and authors' comments are available to view on publication of the final document. Dr Brian Rous Clinical Lead for Guideline Review

The Royal College of Pathologists
6 Alie Street, London E1 8QT
Tel: 020 7451 6700
Fax: 020 7451 6701
Web: www.rcpath.org

Registered charity in England and Wales, no. 261035
© 2021, The Royal College of Pathologists

This work is copyright. You may download, display, print and reproduce this document for your personal, non-commercial use. Apart from any use as permitted under the Copyright Act 1968 or as set out above, all other rights are reserved. Requests and inquiries concerning reproduction and rights should be addressed to the Royal College of Pathologists at the above address. First published: 2021.



Contents

Foreword	3
1 Introduction	4
2 Clinical information required on the specimen request form.....	5
3 Preparation of specimen before dissection.....	5
4 Specimen handling and block selection.....	6
5 Core histological data items.....	10
6 Non-core data items	19
7 Small biopsy specimens	20
8 Reporting of frozen sections	21
9 Specific aspects of individual tumours not covered elsewhere.....	21
10 Criteria for audit	22
11 References	23
Appendix A TNM and FIGO pathological staging of cervical carcinoma.....	29
Appendix B WHO classification of cervical epithelial tumours and SNOMED-CT coding	34
Appendix C Reporting proforma for cervical cancer in excisional cervical biopsies.....	36
Appendix D Reporting proforma for cervical cancer in hysterectomy specimens	38
Appendix E Reporting proforma for cervical cancer in excisional cervical biopsies in list format ..	40
Appendix F Reporting proforma for cervical cancer in hysterectomy specimens in list format	45
Appendix G Summary table – Explanation of grades of evidence	52
Appendix H AGREE II guideline monitoring sheet	53



NICE has accredited the process used by the Royal College of Pathologists to produce its cancer datasets. Accreditation is valid for five years from 25 July 2017. More information on accreditation can be viewed at www.nice.org.uk/accreditation.

For full details on our accreditation visit: www.nice.org.uk/accreditation.

Foreword

The cancer datasets published by the Royal College of Pathologists (RCPATH) are a combination of textual guidance, educational information and reporting proformas. The datasets enable pathologists to grade and stage cancers in an accurate, consistent manner in compliance with international standards and provide prognostic information, thereby allowing clinicians to provide a high standard of care for patients and appropriate management for specific clinical circumstances. This guideline has been developed to cover most common circumstances. However, we recognise that guidelines cannot anticipate every pathological specimen type and clinical scenario. Occasional variation from the practice recommended in this guideline may therefore be required to report a specimen in a way that maximises benefit to the patient.

Each dataset contains core data items (see Appendices C–F) that are mandated for inclusion in the Cancer Outcomes and Services Dataset (COSD – previously the National Cancer Data Set) in England. Core data items are items that are supported by robust published evidence and are required for cancer staging, optimal patient management and prognosis. Core data items meet the requirements of professional standards (as defined by the Information Standards Board for Health and Social Care [ISB]) and it is recommended that at least 95% of reports on cancer resections should record a full set of core data items. Other non-core data items are described. These may be included to provide a comprehensive report or to meet local clinical or research requirements. All data items should be clearly defined to allow the unambiguous recording of data. The recommendations are in line with those of other national pathology organisations and are detailed in the dataset produced by the International Collaboration on Cancer Reporting (ICCR), and the upcoming best practice guidelines put forward by the International Society of Gynecological Pathologists (ISGyP).¹

The following stakeholders were contacted to consult on this document:

- British Association of Gynaecological Pathologists (BAGP)
- National Health Service Cervical Screening Programme (NHSCSP)
- British Society for Cytopathology (BAC)
- British Society for Colposcopy and Cervical Pathology (BSCCP)
- British Gynaecological Cancer Society (BGCS).

Evidence for the revised dataset was obtained from a review of relevant literature up to 2019. The evidence has been evaluated according to the modified SIGN guidance (see Appendix G). Most of the supporting evidence is grade C or D, or meets the good practice point criteria. Consensus of evidence in the datasets was achieved by expert review. The sections of this dataset that indicate compliance with each of the AGREE II standards are indicated in Appendix H.

No major organisational changes or cost implications have been identified that would hinder the implementation of the dataset.

A formal revision cycle for all cancer datasets takes place on a three-yearly basis. However, each year, the College will ask the authors of the dataset, in conjunction with the relevant subspecialty adviser to the College, to consider whether or not the dataset needs to be revised. A full consultation process will be undertaken if major revisions are required, i.e. revisions to core data items (the only exception being changes to international tumour grading and staging schemes that have been approved by the Specialty Advisory Committee on Cellular Pathology and affiliated professional bodies; these changes will be implemented without further consultation). If minor revisions or changes to non-core data items are required, an abridged consultation process will be undertaken, whereby a short note of the proposed changes will be placed on the College website for two weeks for members' attention. If members do

not object to the changes, the changes will be incorporated into the dataset and the full revised version (incorporating the changes) will replace the existing version on the College website.

The dataset has been reviewed by the Clinical Effectiveness team, Working Group on Cancer Services and Lay Network. It was placed on the College website for consultation with the membership from 29 September to 27 October 2020. All comments received from the stakeholders and membership were addressed by the authors to the satisfaction of the Chair of the Working Group and the Clinical Lead for Guideline Review.

This dataset was developed without external funding to the writing group. The College requires the authors of datasets to provide a list of potential conflicts of interest; these are monitored by the Clinical Effectiveness team and are available on request. The authors of this document have declared that there are no conflicts of interest.

1 Introduction

This document provides the datasets for the histological reporting of cervical cancers in small excision, trachelectomy and hysterectomy specimens. It replaces the previous dataset of 2011.

Meticulous reporting of cervical cancers is important since gross pathological and histological parameters determine patient treatment. Accurate recording of pathological parameters in the datasets has both direct and indirect implications for the prognosis of individual patients. The use of datasets (and the background information that forms part of the datasets) in the context of multidisciplinary team (MDT) meetings is advocated to optimise decisions related to patient treatment, to facilitate regular audit and review of all aspects of the service, to enable the collection of accurate data for cancer registries and to provide feedback for those caring for patients with cancer. It is important to have robust local mechanisms in place to ensure that the MDT clinical leads and cancer registries are apprised of supplementary or revised histology reports that may affect patient treatment and data collection.

Revised datasets are largely based on the preceding version. The salient changes in this version are given below:

- the presentation of data items in the small excision specimen protocol has been reordered so that invasive tumours are covered before pre-invasive lesions. Some data items have been removed because of recent developments in the NHS Cervical Screening Programme (NHSCSP), e.g. the implementation of cervical cancer audits, in which changes associated with human papilloma virus (HPV) infection and epithelial changes of uncertain significance are included. Details regarding tumour margins have been expanded and clarified in the dataset and cover the reporting of cervical cancer in loop/cone biopsies and hysterectomy specimens.
- the use of the term 'microinvasive carcinoma' continues to be discouraged. We recommend using the International Federation of Gynecology and Obstetrics (FIGO) stage as a specific descriptor of small invasive carcinomas.
- the classification of cervical carcinomas has been updated to World Health Organisation (WHO) 2020²
- clinical relevance of characterisation of carcinomas as HPV-associated (HPVA) and HPV independent (HPVI) cancers and their clinical significance has been included³
- pattern-based assessment of cervical adenocarcinomas has been included⁴
- sentinel lymph node (SLN) protocol has been included⁵

- p16 interpretation has been included⁶
- cancers are staged according to tumour, node and metastasis (TNM) classification (an anatomical staging system developed by the Union of International Cancer Control [UICC] and FIGO). TNM and FIGO staging of gynaecological cancers was recommended to allow standardisation of staging across all cancer sites;^{7,8} however, surveys carried out on behalf of the BAGP and BGCS were overwhelmingly in favour of using FIGO staging alone for all gynaecological cancers, except cervical carcinoma. Therefore, this dataset recommends that both FIGO and TNM staging are included in the pathology report. However, the final decision is left to the discretion of the pathologist and the preference of their MDT.⁹
- FIGO published a staging revision in 2018.⁸ The changes made to the 2009 system¹⁰ by FIGO in 2018 were implemented across the UK on 1 January 2020. The salient changes are assessment of stage IA disease on the basis of depth of stromal invasion only, the subdivision of stage IB into three size categories and the inclusion of lymph node metastasis (identified by imaging or pathology) in stage III. Clinical management decisions are currently based on FIGO 2018 staging system.⁸

1.1 Target users and health benefits of these guidelines

The target primary users of the dataset are trainee and consultant pathologists who are dealing with and reporting these tumours and, on their behalf, the suppliers of IT products to laboratories. The secondary users are surgeons, oncologists, cancer registries and the National Cancer Registration and Analysis Service (NCRAS). Standardised cancer reporting and MDT working reduce the risk of histological misdiagnosis and help ensure that clinicians have all the relevant pathological information required for tumour staging, management and prognosis. Collection of standardised cancer-specific data provides information for healthcare providers and epidemiologists, and facilitates international benchmarking and research.

2 Clinical information required on the specimen request form

This should include full patient details, cervical screening history (if available), clinical appearance of the cervix, the results of previous biopsies and radiological investigations that have been carried out for tumour staging and colposcopic appearances. Details of previous surgical and non-surgical treatments should be provided as these may influence evaluation of the current specimen, including measurement and staging. Comprehensive details of the surgical procedure should be included with details of surgical specimens from multiple sites and specimen pots should be labelled to correspond to the specimen details on the request form.

3 Preparation of specimen before dissection

Cervical specimens include biopsies, loop/cone excisions, trachelectomies, simple and radical hysterectomies and pelvic exenterations. The usual surgical procedure for cervical carcinoma (FIGO 2018 stages IA2 and IB) is a radical hysterectomy and lymph node dissection. Adjacent organs may be involved in some cases of advanced cervical tumours. If adherent or adjacent organs are attached, these will need to be opened (to allow fixation) in a way that will not compromise resection margins.

Preparation of radical hysterectomy specimens will depend on the size of the cervical tumour and the extent of spread. Parametrial and vaginal margins may require painting with ink or dye before opening the uterus (this may be done before sampling to allow adequate fixation of the corpus).

Opening of the uterus should allow optimal visualisation of the cervical tumour and facilitate block taking to ensure that all of the core data items can be assessed. There is no one proscriptive method of opening the uterus. It may be appropriate to open the uterus in the sagittal plane for large tumours, but more advantageous to open the uterus in the coronal plane for very small tumours or tumours that are not obvious macroscopically. Some pathologists advocate amputation of the cervix before opening the uterus, so the cervix can be dissected and processed in a similar way to a cone or loop biopsy. However, this will depend on tumour size – large, bulky tumours may not be amenable to sampling in this way.

A photographic record of the specimen may be useful.

4 Specimen handling and block selection

Cone and loop biopsies are performed mainly for pre-invasive lesions, but occasionally an early invasive carcinoma is identified. Wedge biopsies are rarely done nowadays.

Trachelectomies are being increasingly performed. Handling of a trachelectomy specimen is similar to the handling of the cervix in a radical hysterectomy specimen.

4.1 Gross examination and dissection of excisional cervical biopsy specimens (cone/LLETZ/loop biopsy)

The number of pieces of tissue must be indicated on the proforma. A second, separate loop biopsy may be taken from beyond the apex of the more superficial loop biopsy (so-called ‘top hat’) and both specimens should be processed in the same way. In some cases, more than two pieces of tissue may be received. All specimens should be measured in three dimensions and must be examined in their entirety. The block designation of each separate specimen must be provided (e.g. first piece: blocks A–C; second piece: blocks D–F, etc.). This is particularly important for the reviewer in case there is a need for internal or external review.¹¹

There are several methods of dissection of cone and loop biopsies (whether received opened or closed). The commonest method is serial slicing at 2–3 mm intervals, from one edge to the other in a sagittal and parasagittal plane (beginning at the three or nine o’clock edge, which should be noted, particularly if the 12 o’clock position has been marked by the surgeon), perpendicular to the transverse axis of the external os. This method avoids the interpretation problems that can occur when dysplastic epithelium arises on the narrow end of a wedge-shaped block (if a loop/cone specimen is sectioned radially, see below), and facilitates assessment of tumour volume in small lesions.¹² However, this method does not allow direct correlation of cervical intraepithelial neoplasia (CIN), cervical glandular intraepithelial neoplasia (CGIN) or tumour with the specific position on a clock face that the second radial method of sampling permits.¹³ In this technique, wedge-shaped slices are taken according to the hours on a clock face. In practice, determination of the position of a cervical lesion is very rarely of relevance to subsequent treatment or management.

In either case, the slices should be submitted in sequential, individually designated cassettes to ensure that the sequential faces of consecutive slices are blocked and cut for histology and allow measurement of the third dimension of cervical tumours when necessary. The slices should be embedded such that there are no apposing faces except for one end slice and its adjacent slice. In some, the excision margins of loop biopsies are assessed by embedding the outer (curved) surface of the first and last slices of the loop face down for sectioning, instead of the cut surface. In a few institutions, the curved edge slices are processed as multiple cruciate slices of 2–3 mm thickness made perpendicular to the sagittal plane. Local protocols should clearly state the

manner of cutting and embedding. If more than one slice is placed in an individual cassette, local protocols should be in place so that it is known unequivocally which slices are adjacent and consecutive. These protocols must be provided when cases are sent for review.

4.2 Gross examination and dissection of hysterectomy specimens

The specimen components (usually vaginal cuff, uterus, parametria, fallopian tubes and ovaries), their dimensions and gross appearances should be recorded and checked for consistency with the details in the specimen request form. The presence of any gross abnormality should be recorded. Surgically dissected parametrium consists of node-bearing fat and soft tissue. Formal parametrectomy is not a part of a simple hysterectomy. Fragments of parametrial soft tissue may be included in a simple hysterectomy specimen and can be submitted as parametrial shaves. Lymph nodes usually include the pelvic nodes (including obturator, internal, common or external iliac, presacral and lateral sacral). Non-regional nodes (para-aortic, inguinal or other nodes) may also be sent. Nodes are usually sent in separate pots and labelled as to their sites of origin.

Measurements should include the dimensions of the uterus for hysterectomy and dimensions of the cervix for trachelectomy specimens. The largest (maximum) tumour dimension should be recorded. The minimum and maximum lengths of the vaginal cuff should be documented.¹³ After appropriate measurements have been taken, it may be necessary to trim or remove the vaginal cuff to enable assessment of the cervical tumour. If this is done, the circumferential vaginal resection margin can be blocked in strips for histological assessment of this resection margin. If there is only a short length of vaginal cuff attached to the specimen, trimming will not be necessary, and the vaginal cuff (and resection margin) should be submitted in continuity with the cervix. Particular attention should be paid to the fornices. If there is macroscopic evidence of vaginal involvement, the position and extent of involvement should be recorded. Three dimensions or, as a minimum, the unstretched lateral width of the parametrial tissue on the right and left should be recorded.

The location of the tumour must be documented in all reports. The exact location in the cervix – anterior, posterior, right or left lateral, circumferential – should be mentioned. The location of the tumour with regard to the cervical topography, i.e. endocervical or ectocervical, should be mentioned. Systematic recording of the position of the tumour within the cervix enables audit of, and correlation with, radiological findings. In one study, the risk of lymph node involvement was shown to increase progressively with involvement of one, two, three or four cervical quadrants (from 2% if one quadrant is involved to 13% if three or four quadrants are involved).¹¹

Tumours extending into the uterine corpus and the presence of uterine corpus involvement should be recorded. Parametrial involvement is an indicator of poor prognosis in early-stage cervical carcinoma, regardless of lymph node status, and is an adverse prognostic indicator for advanced stage cervical carcinomas.¹⁵⁻¹⁷

4.3 Block selection for excisional cervical biopsy specimens (cone/loop biopsy)

These specimens should be blocked in their entirety. Cassettes should be separately identified, with a block designation to indicate their origin.

4.4 Block selection for hysterectomy specimens

Blocks of the cervix must be taken to demonstrate the maximum depth of invasion and the relationship of the tumour to the surgical resection margins, notably the vaginal, anterior cervix/bladder reflection, posterior cervix/rectovaginal septum and parametrial margins.

For small tumours and in cases where no macroscopic tumour is identified, the whole of the cervix should be blocked as in the case of cone/loop biopsies. For large, bulky tumours at least one section per centimetre of greatest tumour dimension should be blocked to include, if possible, the point of deepest invasion, i.e. full thickness of the cervical wall. Additional blocks should include the interface with adjacent normal appearing cervix in order to demonstrate any CIN or CGIN from which the carcinoma may have arisen. Full thickness sections from the lower uterine segment, immediately proximal and adjacent to the tumour, should be taken to identify upward extension.

Blocks of the vaginal resection margin may be taken in continuity with the tumour if the vaginal cuff is short (see above) or separate blocks of the trimmed circumferential vaginal resection margin should be blocked in specifically designated cassettes according to their origin (e.g. from the anatomical quadrants from which they have originated).

Extension into the parametrium should be detected preoperatively. If detected, the patient undergoes non-surgical management.¹⁸ Formal parametrectomy is not a part of the simple hysterectomy procedure. Parametrial tissue is removed in radical hysterectomy and should be blocked in its entirety. Wisps of parametrial tissue removed as a part of simple hysterectomy should be blocked in their entirety as parametrial shaves.¹¹ The laterality of the blocks must be recorded and inking may be helpful to define the true surgical margins.

The uterine corpus and adnexa should be sampled according to standard protocols if uninvolved.¹⁹ Additional blocks may be required if there is evidence of involvement by tumour.

The number of lymph nodes retrieved from each site should be recorded. The presence of macroscopic involvement of lymph nodes should be noted, together with the dimensions of involved nodes. The size of the involved lymph nodes has been found to be significant in one study.²⁰ All resected lymph node tissue should be sampled and all lymph nodes from each location must be blocked. Each individual lymph node should be examined histologically in its entirety unless obviously grossly involved by tumour. Only one block is necessary from any grossly involved node. Nodes smaller than 4 mm should be bisected. Larger lymph nodes should be sampled completely after slicing at 2 mm intervals and embedding the slices sequentially. The fat applied to the nodes should be retained so that extranodal extension can be assessed. A decision on handling the accompanying adipose tissue is best left to departmental protocols as there is no universal consensus on this matter.

In departments where the facility for processing of oversize blocks is available, a good overview of the tumour and resection margins can be obtained, but standard blocks of tumour should also be processed to enable immunohistochemistry (IHC) or other special stains to be performed more readily, should these be required.

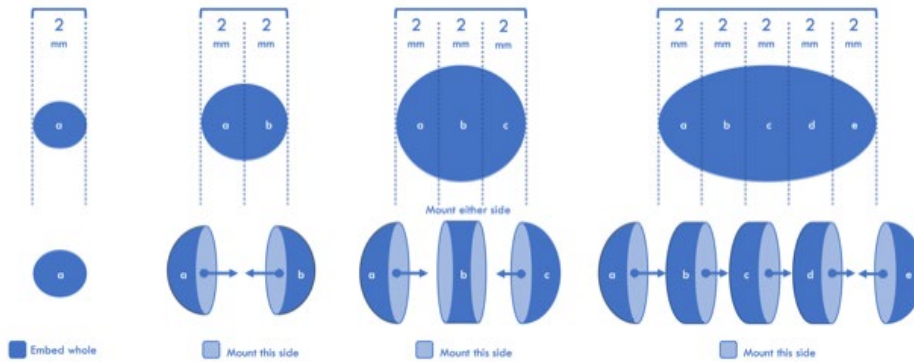
The origin or designation of all tissue blocks should be recorded. This is particularly important if internal or specialist external review is required. The reviewer needs to be clear about the origin, relevant resection margin(s) and laterality of each block to provide an informed specialist opinion

4.5 SLN handling

Many different protocols have been advocated in the published literature. We recommend the use of the protocol jointly recommended by the BAGP and BGCS.⁵ The lymph node and adherent fat should be examined, and the presence and colour of any visible dye should be recorded. Lymph nodes up to 2 mm can be embedded whole. Nodes 2–4 mm in size should be bisected and both halves submitted. Nodes that are 4 mm or more in their largest dimension should be bisected or sliced at 2 mm intervals, in a plane perpendicular to the longest axis (see Figure 1). It is preferable to avoid any trimming of surrounding fat. Overcrowding the cassette (over 80% of the area) must

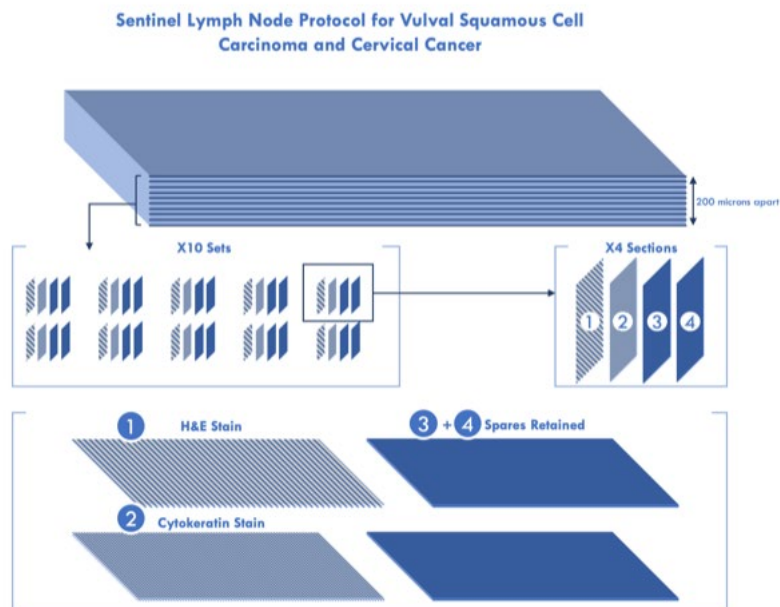
be avoided. When a node is trisected, the two end pieces should be placed cut surface down; the middle slice is placed randomly unless gross examination identifies a suspicious lesion. When more than three slices from a lymph node are submitted, the non-apposing faces should form the cutting surface ensuring that microscopic sections are 2 mm apart and ensuring a high probability of detecting all macrometastases. If multiple nodes are received, these should be processed in separate cassettes and clearly documented in the block index.

Figure 1: Embedding of lymph nodes in sentinel node ultrastaging.



The protocol for ultrastaging is as follows: four sections are cut at 200 micron intervals through the block until all nodal tissue is exhausted; theoretically, this should result in ten additional sets of four slides. One section from every set of four is stained with haematoxylin and eosin (H&E) and one with cytokeratin. Two additional sections are retained at each level in case there is a problem with H&E or IHC staining, or if additional levels are required to see if the focus becomes larger or for further IHC to determine the nature of indeterminate CK-positive cells (Figure 2).

Figure 2: Sentinel lymph node protocol for vulval squamous cell carcinoma and cervical cancer.



5 Core histological data items

5.1 Tumour type

Tumour type should be designated according to the 5th edition of the WHO classification (see Appendix B). The 5th edition of the WHO classification divides carcinomas of the cervix and their precursors on the basis of their association with HPV infection. The carcinomas are divided into HPVA and HPVI categories. This may have clinical implications²¹ and provide better assessment of the use of HPV testing in screening programmes as well as the role of HPV vaccination.

The major tumour types are squamous cell carcinoma (SCC) and adenocarcinoma. Most SCC are HPVA. However, HPVI SCC, although rare, have been described. The WHO classification accepts that morphological distinction between these categories is not possible; use of p16 immunostaining or HPV testing is required. As current treatment strategies do not depend on this distinction, specification of these categories is not mandated when the ancillary techniques are not available. In the UK, however, the HPV status of screen-detected cases is known and p16 is available in most laboratories for non-screen-detected cancers. As a result, every effort should be made to categorise SCC as HPVA or HPVI, and the category of SCC, not otherwise specified (NOS) should be used sparingly.

The new WHO classification separates adenocarcinoma into HPVA and HPVI types. Neuroendocrine tumours, lymphoid tumours, mesenchymal tumours, melanocytic tumours and metastatic tumours are not discussed in the chapter on tumours of the uterine cervix, but mixed epithelial and mesenchymal tumours are retained.

HPVA adenocarcinomas are recognised morphologically by the presence of apical mitoses and karyorrhexis that are conspicuous and identifiable at low power magnification. In well to moderately differentiated areas these consist of glands with smooth luminal profiles and pseudostratified columnar epithelial cells that have enlarged, elongated and hyperchromatic

nuclei. Immunohistochemistry for p16 is helpful but can be strongly and even diffusely positive in HPV1 adenocarcinomas. Histological types of HPV1 adenocarcinomas include usual type and mucinous type. Usual type HPV1 adenocarcinomas account for about 75% cases and include those showing mucin secretion in 0-50% of cells, and villoglandular architecture. Mucinous type HPV1 adenocarcinoma has been subtyped into mucinous NOS adenocarcinoma, intestinal adenocarcinoma (when goblet cell or enteroendocrine cell differentiation represents $\geq 50\%$ of the tumour), signet-ring cell adenocarcinoma (when non-cohesive cells with a signet-ring morphology – cells with cytoplasmic mucin displacing the nucleus to the periphery – represent $\geq 50\%$ of the tumour) and stratified mucin-producing carcinoma (when the invasive tumour consists of nests of stratified epithelium with intracytoplasmic mucin).

HPV1 adenocarcinomas comprise gastric type, clear cell, mesonephric and endometrioid type. Gastric type adenocarcinoma is defined as one showing gastric/pyloric differentiation unrelated to HPV; this may be characterised morphologically or through demonstration of neutral mucin (pinkish-red on Alcian Blue/PAS staining; endocervical mucin is acidic and stains dark purple). This is characterised by cells with abundant pale or clear cytoplasm and distinct cell borders. Apical mitotic figures and apoptosis are seen but are not a conspicuous feature. The architecture ranges from extremely well differentiated (previously called 'minimal deviation' adenocarcinoma, a term no longer recommended) to poorly differentiated.

Clear cell adenocarcinomas may occur sporadically or rarely following in utero exposure to diethylstilbestrol. These are similar to clear cell carcinomas occurring in other parts of the female genital tract, characterised by tumour cells with abundant clear, eosinophilic or granular cytoplasm arranged in a tubulocystic pattern often with a 'hobnail' luminal outline.

Mesonephric carcinomas are typically associated with mesonephric remnants and occur in the lateral walls of the cervix. Typically, these show a tubular pattern with luminal eosinophilic secretions and a variety of additional architectural patterns may be seen. The cells are cuboidal and relatively uniform with inconspicuous nucleoli and variable mitotic activity.

Endometrioid adenocarcinomas are rare and account for less than 1% of all primary endocervical adenocarcinomas. They are believed to be associated with endometriosis. Diagnosis of endometrioid adenocarcinoma of the cervix requires at least focal low-grade endometrioid glands lined by columnar cells with pseudostratified, bland nuclei, with or without squamous differentiation and/or cervical endometriosis, patchy p16 staining and exclusion of an endometrioid carcinoma of the endometrium. HPV1 adenocarcinomas with mucin depletion can be mistaken for endometrioid carcinomas, but lack confirmatory endometrioid features, lack association with endometriosis and show block positive staining with p16.

Serous carcinoma, adenofibroma and adenocarcinoma NOS have been omitted from the classification. Serous carcinoma has been removed as there is lack of evidence that it occurs as a primary tumour. Adenofibromas have been omitted as they can be distinguished from common endocervical polyps and adenosarcomas only on hysterectomy specimens. Cervical adenocarcinomas are divided into HPV1 and HPV1 types, thus discouraging the NOS category.

Since there is no evidence that an HPV1 preneoplastic squamous lesion exists, squamous intraepithelial lesions are grouped into a single HPV1 category – cervical intra-epithelial neoplasia (CIN). Based on morphology, association with HPV types and risk of progression to invasive carcinoma, they are categorised as CIN1 (low-grade squamous intraepithelial lesion), CIN2 and CIN3 (high-grade squamous intraepithelial lesion).

Precursors of adenocarcinoma have been divided into HPV1 and HPV1 groups. HPV1 CGIN is maintained as a single category – adenocarcinoma in situ (AIS)/high-grade CGIN. These terms

are synonymous, and the preferred UK terminology is CGIN. When goblet cells are present, this is termed high-grade CGIN (AIS) with intestinal differentiation. Stratified mucin-producing intraepithelial lesion (SMILE) is regarded as a subtype of high-grade CGIN. At low power magnification, this may resemble CIN3 involving endocervical glands/clefts; however, at higher magnification, intracytoplasmic mucin is usually obvious. Nuclear atypia, hyperchromasia, mitoses and apoptotic bodies are also present. SMILE may co-exist with CIN3, high-grade CGIN or invasive carcinoma.

Precursors of HPV1 adenocarcinoma are known as AIS HPV1 and synonyms include gastric-type AIS and atypical lobular endocervical glandular hyperplasia. Typically, they are composed of cuboidal to columnar cells with distinct cell borders, and an eosinophilic to pale and/or foamy vacuolated cytoplasm. Nuclear atypia ranges from mild to severe. Mitoses and apoptosis may be inconspicuous. The preneoplastic cells colonise pre-existing glands and thus architectural abnormalities of the crypt field are not seen. On immunohistochemistry, the cells are positive for the pyloric marker HIK1083, often positive for PAX8 and CDX2, and usually negative for oestrogen and progesterone receptors. p16 staining is typically non-block. Aberrant or mutation-type p53 staining can often be seen.

[Levels of evidence – B and C.]

5.2 Tumour grade

Tumour grade is always included in reports of carcinomas. In cervical carcinomas, there is no universally accepted grading system and grading of these tumours remains of uncertain clinical value.²²

While no grading system has a close correlation with prognosis and interobserver variability is likely to be significant, oncologists and gynaecological oncologists often insist on the tumour being graded. The current ICCR recommendations state that squamous carcinomas should not be graded. This is because grading as well-differentiated (keratinising), moderately or poorly differentiated using a modified version of Broders' grading system²³ may be misleading since cervical squamous epithelium is not normally keratinised, and the absence of keratinisation may not therefore represent a poor prognostic feature.

According to ISGyP recommendations, HPV1 adenocarcinomas should be graded by their architecture similar but not identical to the grading system used for endometrial endometrioid carcinomas. Carcinomas with less than 10% solid growth are grade 1, those between 11% and 50% are grade 2 and those with solid growth greater than 50% are grade 3.²⁴ It may not be possible or relevant to grade very small carcinomas of squamous or glandular type and in such situations, it is recommended that tumours are graded as GX (grade cannot be assessed). There is also an implicit correlation between grade and type of carcinoma. A diagnosis of villoglandular adenocarcinoma is always low grade while gastric-type adenocarcinomas and neuroendocrine carcinomas behave aggressively and are considered high grade.

[Levels of evidence – B and C.]

5.3 Tumour dimensions

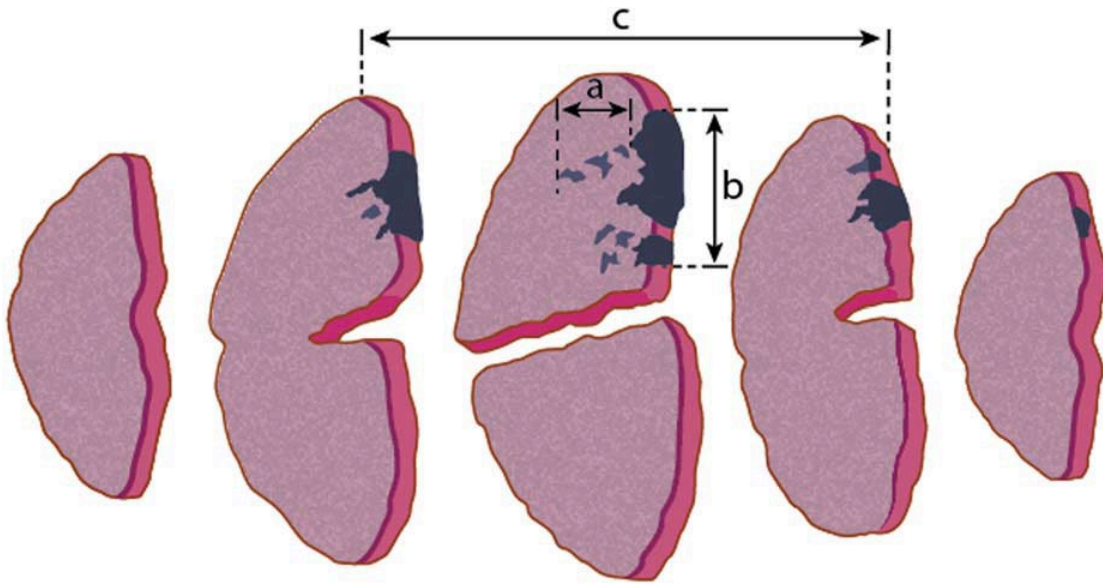
In cervical carcinoma, tumour dimensions are important for accurate staging, patient management and prognosis.²⁵ Following radical trachelectomy, the recurrence rate is statistically higher with a tumour size >2 cm and rates of adjuvant treatment are higher.^{26,27}

Tumour measurements are especially important in distinguishing between FIGO (2018) stage IA1, IA2 and IB neoplasms since FIGO IA1 neoplasms are treated by local excision while FIGO IA2 and IB neoplasms are treated by radical trachelectomy or hysterectomy. In the 2018 FIGO staging system, the horizontal dimension is no longer considered when defining the upper boundary of a stage IA carcinoma.⁸ It is stated in the 2018 revised FIGO staging article that if the margins of an excision biopsy show invasive carcinoma, FIGO stage IB1 is allocated; this is not, however explicitly tabulated in the staging criteria. In order to avoid over- or under-staging, when small cancers involve resection margins staging should be offered a provisional stage. Staging should be completed at MDT with clinical and radiological assessment or after due correlation with findings on subsequent excision or resection specimens.

Large tumours can be accurately measured grossly. Small tumours and some large tumours, especially those with a diffusely infiltrative pattern, may only be measurable microscopically. The pathologist should decide whether a tumour should be measured macroscopically or microscopically and indicate this on the report; only a single maximum dimension should be provided. In cases in which tumours are treated by primary chemoradiation and only a small confirmatory biopsy has been taken, the tumour dimensions are based on clinical or radiological assessment. This is also valid when resection performed after chemoradiation does not reveal any residual tumour.

Tumours should be measured in millimetres in three dimensions, and two measurements should be provided in the report: the largest horizontal dimension and the invasive depth/thickness.

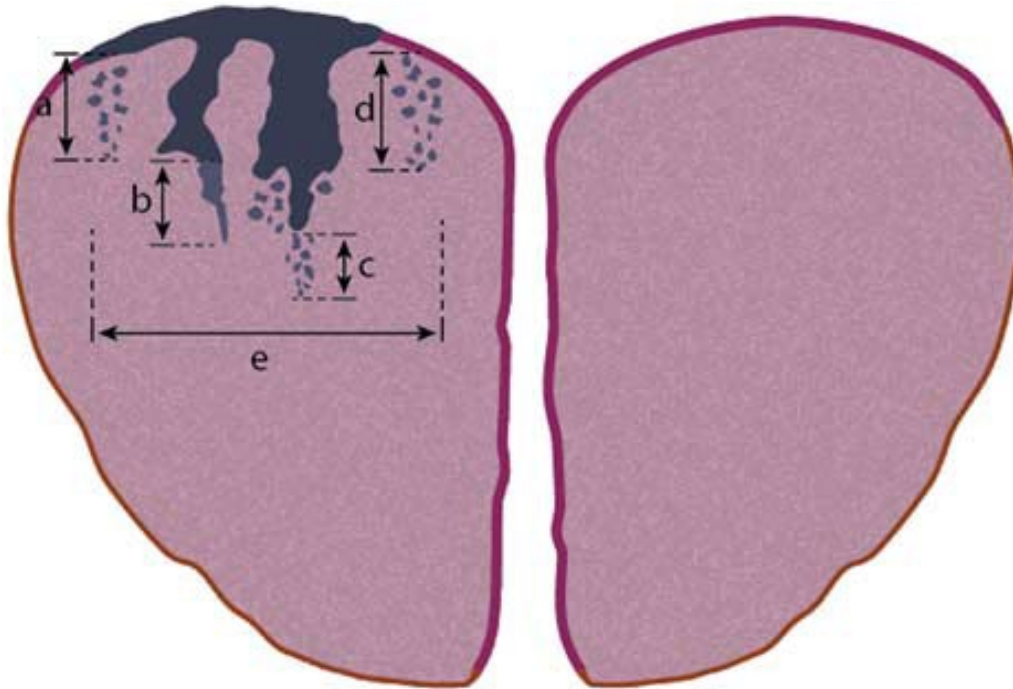
Figure 3: Measurement of cervical tumours in three dimensions.



CIN 3 with involvement of endocervical gland crypts is represented by the dark blue coloured areas, nondysplastic squamous epithelium is pink, and grey areas indicate foci of stromal invasion. The depth of invasion (a) and horizontal tumour dimension/width (b) are measured in unifocal disease. Another horizontal dimension is determined calculating the block thickness (usually 2.5–3.0 mm) and multiplying this by the number of sequential blocks involved by the carcinoma. The horizontal dimension is not used in determining stage I cervical carcinoma in FIGO 2018 system.

This figure was reproduced with the permission of the International Collaboration on Cancer Reporting. It was first published in McCluggage WG, Judge MJ, Alvarado-Cabrero I, Duggan MA, Horn LC, Hui P *et al.* Data set for the reporting of carcinomas of the cervix: recommendations from the International Collaboration on Cancer Reporting (ICCR). *Int J Gynecol Pathol* 2018;37:205–228.¹¹

Figure 4: Measurement of depth of invasion and horizontal dimension in one slice of tissue.



The dark grey surface represents CIN 3 with involvement of endocervical gland crypts and the lighter grey, cross-hatched surface, non-dysplastic squamous epithelium. Black areas indicate foci of stromal invasion.

When the origin of the tumour is identified as being from the surface epithelium or gland crypt, the depth of invasion is taken from the base of the epithelium from which the carcinoma arises, to the deepest focus of invasion, as specified in the FIGO classification. Measurements are taken in the same way whether or not the invasive foci remain attached to the gland crypt (b) or have broken away from a gland crypt (c). When a surface epithelial origin is evident, depth of invasion is measured from the base of the surface epithelium to the deepest point of invasion (a). When no obvious surface (or crypt) epithelial origin is seen, the depth of invasion is measured from the deepest focus of tumour invasion to the base of the nearest non-neoplastic surface epithelium (d). Maximum horizontal dimension/width (e) is measured in the piece of tissue in which the width is greatest (from the edge at which invasion is first seen to the most distant edge at which invasion is identified), in sections where the foci of invasion are arising in close proximity to each other, even if the foci of invasion are separated by short stretches of normal epithelium.

This figure was reproduced with the permission of the International Collaboration on Cancer Reporting. It was first published in McCluggage WG, Judge MJ, Alvarado-Cabrero I, Duggan MA, Horn LC, Hui P *et al.* Data set for the reporting of carcinomas of the cervix: recommendations from the International Collaboration on Cancer Reporting (ICCR). *Int J Gynecol Pathol* 2018;37:205–228.¹¹

Depth of invasion is taken from the base of the epithelium (surface or glandular) from which the carcinoma arises, to the deepest point of invasion, as specified in the FIGO classification. When the invasive focus is in continuity with the dysplastic epithelium from which it originates, this measurement is straightforward. The measurement is taken from the deepest point of invasion to the base of the surface epithelium. If the invasive focus or foci are not in continuity with the dysplastic epithelium, the depth of invasion should be measured from the tumour base (deepest

focus of tumour invasion) to the base of the nearest dysplastic crypt or surface epithelium. If there is no obvious epithelial origin, i.e. no dysplasia in the immediate vicinity in the plane of sectioning, depth is measured from the tumour base (deepest focus of tumour invasion) to the base of the nearest non-neoplastic surface epithelium. Horizontal dimension/width in unifocal tumours is measured in the slice of tissue in which the width is greatest (from the edge at which invasion is first seen to the most distant edge at which invasion is identified), in sections where the foci of invasion arise in close proximity to each other, even if those foci are separated by short stretches of normal epithelium.

There are some situations in which it is impossible to measure the depth of invasion. These include adenocarcinomas since it is difficult to assess where the CGIN ends and invasion begins, in ulcerated tumours lacking overlying epithelium and in polypoid carcinomas.¹¹ In such cases, the tumour thickness may be measured and this should be clearly stated on the pathology report along with the reasons for providing the thickness rather than the depth of invasion. In such cases, the pathologist and clinician should equate the tumour thickness with depth of invasion for staging and management.

In calculation of the final tumour dimensions in hysterectomy or trachelectomy specimens, it is recommended that depth of invasion is taken as the maximum depth of invasion in the different specimens and the horizontal dimension is taken as the sum of the horizontal dimension of the two specimens.¹¹

Up to 25% of carcinomas with early invasion may be multifocal in origin, i.e. more than one separate focus of invasion is seen.^{28,29} The difficulty is in judging whether these individual foci of invasion arising in a field of dysplasia will over time coalesce to form a single focus of disease.

Multifocal tumours must be diagnosed when after examination of multiple levels:

- the foci of invasion are separated by blocks of uninvolved cervical tissue
- the foci of invasion are located on separate cervical lips with the discontinuous foci not involving the curvature of the canal
- the foci of invasion are situated far apart from each other in the same section.

With the implementation of the 2018 FIGO staging system, these variations have become redundant in the diagnosis of stage I cancers since horizontal dimension is no longer considered.

Accurate staging of tumours in loop biopsies that have been submitted in two or more fragments may be problematical. If invasive carcinoma is present in several of the fragments, measurements of the largest horizontal dimension and maximum depth of invasion should be provided. Such cases must be discussed individually at the MDT meeting and may require re-staging at the MDT based on additional clinical information and imaging.

The use of the term 'microinvasive carcinoma' continues to be discouraged as it has different connotations in different countries and clinical groups. The RCPATH recommends all carcinomas be referred to by their FIGO stage.

[Levels of evidence – B and C.]

5.4 Lymphovascular space invasion

The significance of lymphovascular space invasion (LVSI) in cervical carcinoma is generally accepted as an independent predictor of adverse outcome.^{30–34}

This correlation is particularly valid in FIGO stage IB cancers.³² In FIGO stage IA carcinomas, the significance is unclear as this group of tumours are rarely associated with lymph node metastases or adverse events. In FIGO stage IA1 cancers, LVSI does not predict lymph node metastasis.^{35,36}

The variability in recognition of LVSI is likely to be one of the factors that contributes to the conflicting outcomes noted in various studies. LVSI is recognised by the presence of a group of tumour cells within a space lined by endothelial cells, adherence of the tumour cell group to one side of the space, contour of the group of cells to the contour of the vessel, presence of adherent fibrin and the association of the space with other vessels. Immunohistochemical demonstration of endothelial lining by D2-40 (recognising lymphatic endothelium) and CD31 or CD34 (recognising both lymphatic and blood vessel endothelium) can help but is not performed routinely.^{37,38} Fixation retraction artefact is a mimic of LVSI. In some cases, trauma and diathermy artefact may result in a situation in which LVSI cannot be reliably confirmed. In such cases, which are expectedly rare, this is best recorded as indeterminate.

When identified, it is useful to record the number of vessels involved, either numerically or semi-quantitatively, since the number of involved vessels correlates with the likelihood of nodal metastasis.³⁹

[Level of evidence – C.]

5.5 Resection margins

The status of all resection margins (the minimum tumour-free rim, vaginal and radial resection margins) must be documented in the proforma. Depending on its position, the closest radial margin may consist only of the minimum thickness of uninvolved cervical stroma. In hysterectomy specimens, if the closest radial margin is lateral, the thickness of any previously trimmed paracervical tissue must be added to the measurements that are taken from the relevant histological section. The position of closest margins must be indicated.

In cone/loop biopsies, the status of ectocervical, endocervical and deep lateral/radial resection margins should be recorded, as should their involvement by CIN, CGIN, SMILE or invasive carcinoma. In some situations, for example when there is epithelial stripping or electrothermal artefact, it may not be possible to assess whether there is resection margin involvement by in-situ neoplasia. In such circumstances, it may be helpful to include this information in the text of the histology report. For carcinomas that are identified in loop or cone biopsies, completeness of excision should be documented in the pathology report. Although there is no evidence in the literature to indicate an optimum or 'safe' margin of clearance of carcinomas that are identified in such specimens, for stage IA and IB cervical carcinomas that appear completely excised in loop or cone biopsies, the distance to the closest excision margin should be documented. The report should also state the location of the closest excision margin (ectocervical, endocervical or deep lateral/radial margin). If the margin cannot be assessed owing to processing or other artefacts, it should be specified as 'cannot be assessed' and the reason stated.

An exact figure that defines a 'clear' margin is currently not available. However, in a study of 284 patients with FIGO 2009 stage IB carcinomas, a clearance cut off of 1 cm showed that patients with a margin of 1 cm or less had a crude recurrence rate of 20% but those with a margin greater than 1 cm had a crude recurrence rate of 11%.⁴⁰ In a more recent study of 119 patients with FIGO 2009 stage IA2 to IIA cancers undergoing radical hysterectomy, a margin of 5 mm or less was associated with a recurrence rate of 24% compared with 9% for margins more than 5 mm.⁴¹

[Level of evidence – C.]

5.6 Lymph nodes

Lymph node status is one of the most important prognostic factors for survival in patients with cervical carcinoma. The presence of nodal metastases reduces the five-year survival rate from 85% to 50%.^{42,43}

In the TNM staging system, involvement of a regional lymph node (paracervical, parametrial and various pelvic lymph node groups, including obturator, internal, common or external iliac, presacral, and lateral sacral) contributes to the N category while involvement of a non-regional node is regarded as a distant metastasis (M1).^{10,44} The 2018 FIGO staging system includes nodal status and the presence of nodal involvement (by pathology or imaging) in a tumour of any size upstages the case to stage IIIC, with IIIC1 indicating pelvic and IIIC2 indicating para-aortic nodal involvement. The 2018 FIGO staging is thereby now more closely aligned with the structure of the TNM classification.⁸

There is no internationally accepted minimum number of resected lymph nodes at surgery for cervical cancers. According to the Union for International Cancer Control (UICC), a pelvic lymphadenectomy will include at least six nodes. Irrespective of the actual count, N0 is applied if the resected lymph nodes do not contain a metastasis.

SLN can be defined as the first lymph node or group of lymph nodes in the lymphatic basin that receives the lymphatic flow from an area. The incidence of pelvic nodal spread in FIGO stage I cervical cancer is in the order of 10%.^{45,46} As for other sites, SLN biopsy offers an alternative to full lymph node dissection and its attendant morbidity. This procedure has a high sensitivity and negative predictive value. It is undertaken in patients with presumed low-stage cervical cancer as standard of care.⁴⁷⁻⁴⁹ Ultrastaging improves the detection of micrometastases (defined as having a size of more than 0.2 mm but not greater than 2 mm), which in different studies are noted to be in 8–15% cases.⁵⁰ Cases with micrometastases have been shown to have a reduced five-year survival.^{51,52} In TNM8 and FIGO 2018 (see Appendix), micrometastases are regarded as lymph node involvement and pN1 (mi).

The presence of individual tumour cells (ITCs) – defined as malignant cells in regional lymph node(s) ≤ 0.2 mm – does not have established prognostic value. ITCs, in common with TNM staging practices at other tumour sites, are regarded as node negative, i.e. pN0(i+).

The presence of extracapsular spread correlates with lower disease-free and recurrence-free five-year survival.^{53,54}

Standardised reporting of lymph node (including SLN) specimens is recommended in the following text format, as seen in the *BAGP Guidance Document: Sentinel Lymph Node Processing and Ultra Staging*.⁵

- total number of lymph nodes on each side:
 - if no lymph node is recovered this should be stated. The use of the term ‘negative sentinel node’ is discouraged as this could be interpreted as both a negative procedure (i.e. no SLN detected at surgery) or a SLN negative for metastasis.
- presence of dye or surgeon notes regarding tracer
- if no metastases are present:
 - no metastatic carcinoma is seen in x lymph nodes
- if metastases are present:

- for macro or micrometastases – metastatic carcinoma is identified in y of z lymph node(s). The largest deposit measures x mm in maximum dimension.
- for ITC – metastatic carcinoma in the form of microscopic clusters and single cells measuring x mm are identified in y of z lymph node(s)
- indeterminate CK positive cells should not be reported; an effort should be made to determine their nature, e.g. dendritic cells, mesothelial cells, macrophages, mast cells, endosalpingiosis, endometriosis
- presence or absence of extranodal extension.

[Level of evidence – C.]

5.7 Staging

FIGO published staging guidance in 2018.⁸ The changes made by FIGO in 2018 are included in this dataset and staging guidelines are provided in the appendix. The 2018 FIGO staging system was implemented in the UK on 1 January 2020.⁵⁵ This ensures that national data collection is consistent across the country and this date was endorsed by the British Gynaecological Cancer Society (BGCS).

[Levels of evidence – C and D.]

5.8 Summary of core data items

For excisional biopsies and hysterectomy specimens:

- tumour type
- tumour grade (HPVA adenocarcinomas)
- tumour dimensions (largest horizontal and invasive depth/thickness)
- status of resection margins
- presence or absence of lymphovascular invasion
- recording tumour type as HPVA or HPVVI.

Additional core data items for hysterectomy specimens:

- minimum tumour-free cervical stroma (tumour-free rim) and position
- closest radial resection margin
- presence or absence of lymph node metastases
- involvement of other organs or tissues
- FIGO/TNM stage.

6 Non-core data items

These may be recorded as a separate comment or within a complementary text report. Such items may include details of previous surgical and non-surgical treatment, the presence of a cone/loop biopsy site within the cervix, extension of the carcinoma into the uterine corpus, the

results of histochemical stains for mucin on poorly differentiated tumours and the results of any immunohistochemical studies.

An additional parameter that has been reported to be of prognostic significance in cervical carcinomas and may be included within a complementary text report is the depth of infiltration in thirds of the cervical wall. This parameter is used to calculate the Delgado score.³⁰ In this study, the disease-free interval was found to be 94.1% for tumours that infiltrated the superficial one third of the cervix, 84.5% for those that infiltrated the middle third and 73.6% for those infiltrating the deep third. In a study of FIGO stage I adenocarcinomas, univariate analysis showed that the thickness of the remaining cervical wall was found to correlate with overall survival. When thickness of the remaining wall was >3 mm, five-year survival was 82%, but when the remaining wall thickness was 1–3 mm, five-year survival decreased to 62%.⁵⁶

Perineural involvement is defined as detection of malignant cells in the perineural space. There is limited evidence regarding the prognostic importance of perineural invasion.⁵⁷ Reporting is recommended as a non-core item.

Tumour volume has been used in the past as a reliable indicator of the amount of disease.⁵⁸ Clinicians do not routinely factor tumour volume into management decisions, and this is best reported as a non-core item.

Usual type endocervical adenocarcinomas have been stratified into a pattern-based system akin to grading that informs management decisions of endocervical carcinoma.⁵⁹ The system consists of stratifying adenocarcinomas into one of three patterns:

- pattern A tumours characterised by well-demarcated glands frequently forming clusters or groups with relative preservation of lobular architecture and lacking destructive stromal invasion or lymphovascular invasion
- pattern B tumours demonstrate localised destructive invasion with or without lymphovascular invasion
- pattern C tumours show diffusely infiltrative glands and associated desmoplastic response with or without lymphovascular invasion.

This pattern-based system has been shown to be reproducible among pathologists and to correlate with the risk of lymph node involvement and outcomes. This may aid management decisions at MDT meetings.^{4,60}

[Level of evidence – C.]

7 Small biopsy specimens

Small colposcopically directed punch biopsies may be up to several millimetres long and 2–4 mm thick. The number of pieces received and their size (in three dimensions) should be recorded. Specimens that are mounted on filter paper before fixation are more likely to be optimally oriented and have a preserved squamocolumnar junction and intact surface epithelium. Fixation in eosin-tinted formalin may facilitate their identification and orientation.⁶¹

If biopsies are >5 mm in dimension, they may be bisected transversely, perpendicular to the mucosal surface, to produce two pieces. All of the biopsy fragments should be processed.

The report should incorporate the macroscopic description of the specimen and confirm the presence of transformation zone unless it is a targeted biopsy. If artefact or epithelial loss impairs the interpretation of the biopsy, this must be stated in the report. The pathologist must report all grades of CIN and/or CGIN; invasive lesions should be reported, typed and graded according to national protocols and guidelines. It is recommended that koilocytosis and HPVA changes are also reported. The pathologist must be mindful of the cytology/screening history and the result of the most recent cytology when writing the histology report, and include all pathological lesions (neoplastic and non-neoplastic) that may be associated with, or account for, the reported cytological abnormalities.

When a biopsy fails to reveal the source of the abnormal cells in a smear, it is important to differentiate between a biopsy that is technically adequate but fails to identify a lesion, and a biopsy that is technically inadequate. The limitations of small punch biopsies in the detection of high-grade CIN should be recognised.⁶² If invasive disease is suspected on the basis of the cytological, colposcopic or histological features, further levels should be examined. As yet, there are no prescribed criteria for adequacy. A size of less than 2 mm, intactness of tissue, lack of artefactual changes and optimal staining should all be taken into consideration.

8 Reporting of frozen sections

In most institutions, frozen sections are not used routinely for the assessment of resection margins. However, in some specialist centres, frozen sections may be used for intraoperative evaluation of the upper limit of trachelectomy specimens. Intraoperative frozen sections may also be performed on clinically suspicious lymph nodes to look for metastasis before proceeding with or abandoning radical surgery. Clinicians should be aware of the limitations of frozen sections in general, and of sampling and interpretational errors since they apply to lymph node frozen sections in particular.

9 Specific aspects of individual tumours not covered elsewhere

9.1 Ancillary studies

9.1.1 p16 immunohistochemistry

P16 is one of the commonly used markers in gynaecological pathology. Block staining (strong, diffuse, cytoplasmic and/or nuclear immunoreactivity) is regarded as p16 positive staining.^{6,63} It is a surrogate marker for the presence of high-risk HPV in malignant and premalignant cervical lesions.⁶⁴ Use of p16 is recommended to classify cervical carcinomas, especially as HPVA or HPVI. It must be borne in mind that non-HPV-related neoplasms such as high-grade serous carcinomas may exhibit positive p16 staining. Occasionally, metaplastic processes in the endocervix, such as tuboendometrioid metaplasia, may mimic CGIN. The use of p16, MIB1 and bcl2 immunostaining may prove helpful in this regard.⁶⁵ Detailed illustrated descriptions of p16 interpretation are available in the *BAGP P16 Interpretation Guide*.⁶⁶

9.1.2 HPV-related cervical versus endometrial adenocarcinoma

In small biopsy samples, it may be necessary to differentiate between primary endocervical adenocarcinoma and endocervical extension from a primary endometrial adenocarcinoma. p16, oestrogen receptors (ER) and progesterone receptors (PR) are the most helpful markers for distinguishing between low-grade endometrioid carcinomas and usual type cervical adenocarcinoma. Low-grade endometrioid carcinomas are p16 negative (mosaic or non-block staining) and ER and PR positive. Vimentin (usually positive in low-grade endometrioid carcinomas and negative in usual type cervical adenocarcinoma) and carcinoembryonic antigen

(usually negative in low-grade endometrioid carcinomas and positive in usual type cervical adenocarcinoma) may also be helpful.^{67,68} When differentiating between high-grade endometrioid carcinomas and usual type cervical adenocarcinoma, p16, ER and PR are not very helpful. High-grade endometrioid and serous carcinomas often show mutant type p53 expression and are negative on HPV testing.

9.1.3 Immunohistochemistry of non-HPV-related cervical adenocarcinoma

Non-HPV-related cervical adenocarcinomas tend to be negative or focally positive with p16. Gastric-type adenocarcinomas may exhibit mutation-type staining with p53.⁶⁹ They are usually positive with gastric markers such as MUC6 and HIK1083 and negative with hormone receptors. Mesonephric adenocarcinomas tend to be negative with hormone receptors and may stain with CD10, calretinin and GATA3.^{70,71} Clear cell carcinomas are usually hormone receptor negative, show wild-type staining with p53 and may be positive with Napsin A.

9.1.4 Immunohistochemistry of cervical neuroendocrine carcinomas

Cervical neuroendocrine carcinomas (NEC) are variably positive with the neuroendocrine markers chromogranin, CD56, synaptophysin and PGP9.5. Of these, CD56 and synaptophysin are the most sensitive, but CD56 lacks specificity. Chromogranin is the most specific neuroendocrine marker but lacks sensitivity, with only about 50% of NEC being positive. Small cell NEC may not stain with commonly used neuroendocrine markers and this does not preclude the diagnosis in cases in which the morphology is typical of high-grade NEC. p63 is a useful marker of squamous cervical neoplasms and may be of use in differentiating small cell NEC (p63 negative) from small cell squamous carcinoma (p63 positive). A large number of cervical high-grade NEC are TTF-1 positive.^{72,73}

9.1.5 Predictive biomarkers

In the near future, pathologists may be required to report on predictive biomarkers such as PD-L1 and HER2 in selected cervical carcinomas. When required, these should be interpreted and reported in accordance with established guidelines.

10 Criteria for audit

The following standards are suggested as some of criteria that might be used in periodic reviews of cervical carcinomas:

- use of p16 and classification of cervical adenocarcinoma and precursors as HPV16 or HPV18
- completeness of histopathology reports expressed as an average proportion of the core data items recorded or as a proportion of the reports that include 100% of the items
 - standard: all reports contain 100% of the items
- completeness of excision of FIGO stage IA1 squamous and adenocarcinomas in loop or cone biopsies. According to NHSCSP Publication Number 20,⁷⁴ FIGO stage IA1 squamous cancer can be managed by local excision techniques if the excision margins are free of both CIN and invasive disease.
 - standard for clear margins: 100%. If margins are involved by CIN, a repeat excision is recommended.

11 References

1. Park KJ, Roma A, Singh N, Gilks CB, Oliva E, Abu-Rustum N *et al.* Tumor Staging of Endocervical Adenocarcinoma: Recommendations From the International Society of Gynecological Pathologists. *Int J Gynecol Pathol.* 2021;40(Suppl 1):S92–S101
2. World Health Organization. *WHO Classification of Tumours of Female Genital Tumours (5th edition)*. Lyon, France: IARC, 2020
3. Stolnicu S, Barsan I, Hoang L, Patel P, Terinte C, Pesci A *et al.* International Endocervical Adenocarcinoma Criteria and Classification (IECC): A New Pathogenetic Classification for Invasive Adenocarcinomas of the Endocervix. *Am J Surg Pathol* 2018;42:214–226.
4. Rutgers JK, Roma AA, Park KJ, Zaino RJ, Johnson A, Alvarado I *et al.* Pattern classification of endocervical adenocarcinoma: reproducibility and review of criteria. *Mod Pathol* 2016;29:1083–1094.
5. The British Association of Gynaecological Pathologists. *BAGP Guidance Document: Sentinel Lymph Node Processing and Ultra Staging*. Available at: www.thebagp.org/download/bagp-sentinel-node-protocol/
6. Singh N, Gilks CB, Wing-Cheuk Wong R, McCluggage WG, Herrington CS. *Interpretation of p16 Immunohistochemistry In Lower Anogenital Tract Neoplasia*. Derby, UK: British Association of Gynaecological Pathologists, 2018.
7. Brierley JD, Gospodarowicz MK, Wittekind C (eds). *TNM Classification of Malignant Tumours (8th edition)*. Oxford, UK: Wiley-Blackwell, 2017.
8. Bhatla N, Aoki D, Sharma DN, Sankaranarayanan R. Cancer of the cervix uteri. *Int J Gynaecol Obstet* 2018;143:Suppl 2:22–36.
9. McCluggage G, Hirschowitz L, Ganesan R, Kehoe S, Nordin A. Which staging system to use for gynaecological cancers: a survey with recommendations for practice in the UK. *J Clin Pathol* 2010;63:768–770.
10. Pecorelli S, Zigliani L, Odicino F. Revised FIGO staging for carcinoma of the cervix. *Int J Gynaecol Obstet* 2009;105:107–108.
11. McCluggage WG, Judge MJ, Alvarado-Cabrero I, Duggan MA, Horn LC, Hui P *et al.* Data set for the reporting of carcinomas of the cervix: recommendations from the International Collaboration on Cancer Reporting (ICCR). *Int J Gynecol Pathol* 2018;37:205–228.
12. Heatley M. Distribution of cervical intraepithelial neoplasia: are hysterectomy specimens sampled appropriately? *J Clin Pathol* 1995;48:323–324.
13. Raspollini MR, Lax SF, McCluggage WG. The central role of the pathologist in the management of patients with cervical cancer: ESGO/ESTRO/ESP guidelines. *Virchows Archiv* 2018;473:45–54.
14. European Society of Gynaecological Oncology, European Society for Radiotherapy and Oncology, European Society of Pathology. *ESGO-ESTRO-ESP Cervical Cancer Guidelines*. Prague, CZ: European Society of Gynaecological Oncology, 2017.

15. Kato T, Watari H, Takeda M, Hosaka M, Mitamura T, Kobayashi N *et al.* Multivariate prognostic analysis of adenocarcinoma of the uterine cervix treated with radical hysterectomy and systematic lymphadenectomy. *J Gynecol Oncol* 2013;24:222–228.
16. Zreik TG, Chambers JT, Chambers SK. Parametrial involvement, regardless of nodal status: a poor prognostic factor for cervical cancer. *Obstet Gynecol* 1996;87:741–746.
17. Kamura T, Shigematsu T, Kaku T, Shimamoto T, Saito T, Sakai K *et al.* Histopathological factors influencing pelvic lymph node metastases in two or more sites in patients with cervical carcinoma undergoing radical hysterectomy. *Acta Obstet Gynecol Scand* 1999;78:452–457.
18. Baiocchi G, de Brot L, Faloppa CC, Mantoan H, Duque MR, Badiglian-Filho L *et al.* Is parametrectomy always necessary in early-stage cervical cancer? *Gynecol Oncol* 2017;146:16–19.
19. Kurman RJ, Ellenson LH, Ronnett BM. *Blaustein's Pathology of the Female Genital Tract*. Boston, USA: Springer, 2011.
20. Song S, Kim J-Y, Kim Y-J, Yoo HJ, Kim SH, Kim JE *et al.* The size of the metastatic lymph node is an independent prognostic factor for the patients with cervical cancer treated by definitive radiotherapy. *Radiother Oncol* 2013;108:168–173.
21. Hu Z, Ma D. The precision prevention and therapy of HPV-related cervical cancer: new concepts and clinical implications. *Cancer Med* 2018;7:5217–5236.
22. Tiltman AJ. The pathology of cervical tumours. *Best Pract Res Clin Obstet Gynaecol* 2005;19:485–500.
23. Stock RJ, Zaino R, Bundy BN, Askin FB, Woodward J, Fetter B *et al.* Evaluation and comparison of histopathologic grading systems of epithelial carcinoma of the uterine cervix: Gynecologic Oncology Group studies. *Int J Gynecol Pathol* 1994;13:99–108.
24. Kurman RJ, Carcangiu ML, Herrington CS, Young RH. *WHO Classification of Tumours of Female Reproductive Organs (4th edition)*. Lyon, France: IARC, 2014.
25. Wagner AE, Pappas L, Ghia AJ, Gaffney DK. Impact of tumor size on survival in cancer of the cervix and validation of stage IIA1 and IIA2 subdivisions. *Gynecol Oncol* 2013;129:517–521.
26. Plante M, Gregoire J, Renaud MC, Roy M. The vaginal radical trachelectomy: an update of a series of 125 cases and 106 pregnancies. *Gynecol Oncol* 2011;121:290–297.
27. Park JY, Joo WD, Chang SJ, Kim DY, Kim JH, Kim YM *et al.* Long-term outcomes after fertility-sparing laparoscopic radical trachelectomy in young women with early-stage cervical cancer: an Asan Gynecologic Cancer Group (AGCG) study. *J Surg Oncol* 2014;110:252–257.
28. Day E, Duffy S, Bryson G, Syed S, Shanbhag S, Burton K *et al.* Multifocal FIGO stage IA1 squamous carcinoma of the cervix: criteria for identification, staging, and its good clinical outcome. *Int J Gynecol Pathol* 2016;35:467–474.
29. Reich O, Pickel H, Tamussino K, Winter R. Microinvasive carcinoma of the cervix: site of first focus of invasion. *Obstet Gynecol* 2001;97:890–892.

30. Delgado G, Bundy B, Zaino R, Sevin B-U, Creasman WT, Major F. Prospective surgical-pathological study of disease-free interval in patients with stage IB squamous cell carcinoma of the cervix: a Gynecologic Oncology Group study. *Gynecol Oncol* 1990;38:352–357.
31. Maiman MA, Fruchter RG, DiMaio TM, Boyce JG. Superficially invasive squamous cell carcinoma of the cervix. *Obstet Gynecol* 1988;72:399–403.
32. Zaino RJ, Ward S, Delgado G, Bundy B, Gore H, Fetter G *et al*. Histopathologic predictors of the behavior of surgically treated stage IB squamous cell carcinoma of the cervix. A Gynecologic Oncology Group study. *Cancer* 1992;69:1750–1758.
33. Singh N, Arif S. Histopathologic parameters of prognosis in cervical cancer – a review. *Int J Gynecol Cancer* 2004;14:741–750.
34. Chernofsky MR, Felix JC, Muderspach LI, Morrow CP, Ye W, Groshen SG *et al*. Influence of quantity of lymph vascular space invasion on time to recurrence in women with early-stage squamous cancer of the cervix. *Gynecol Oncol* 2006;100:288–293.
35. Lee SW, Kim Y-M, Son W-S, You H-J, Kim D-Y, Kim J-H *et al*. The efficacy of conservative management after conization in patients with stage IA1 microinvasive cervical carcinoma. *Acta Obstet Gynecol Scand* 2009;88:209–215.
36. Ostor AG, Rome RM. Micro-invasive squamous cell carcinoma of the cervix: a clinico-pathologic study of 200 cases with long-term follow-up. *Int J Gynecol Cancer* 1994;4:257–264.
37. Lim CS, Alexander-Sefre F, Allam M, Singh N, Aleong JC, Al-Rawi H *et al*. Clinical value of immunohistochemically detected lymphovascular space invasion in early stage cervical carcinoma. *Ann Surg Oncol* 2008;15:2581–2588.
38. Alexander-Sefre F, Singh N, Ayhan A, Salveson H, Wilbanks G, Jacobs I. Detection of tumour lymphovascular space invasion using dual cytokeratin and CD31 immunohistochemistry. *J Clin Pathol* 2003;56:786–788.
39. Scurry J, Hacker N, Barlow E, Friedlander M, Jackson M. Is quantification of lymphovascular space invasion useful in stage 1B2 cervical carcinomas? *J Obstet Gynaecol* 2015;35:377–381.
40. Viswanathan AN, Lee H, Hanson E, Berkowitz RS, Crum CP. Influence of margin status and radiation on recurrence after radical hysterectomy in Stage IB cervical cancer. *Int J Radiat Oncol Biol Phys* 2006;65:1501–1507.
41. McCann GA, Taege SK, Boutsicaris CE, Phillips GS, Eisenhauer EL, Fowler JM *et al*. The impact of close surgical margins after radical hysterectomy for early-stage cervical cancer. *Gynecol Oncol* 2013;128:44–48.
42. Uno T, Ito H, Itami J, Yasuda S, Isobe K, Hara R *et al*. Postoperative radiation therapy for stage IB-IIIB carcinoma of the cervix with poor prognostic factors. *Anticancer Res* 2000;20:2235–2239.
43. Peters III WA, Liu P, Barrett RJ, Stock RJ, Monk BJ, Berek JS *et al*. Concurrent chemotherapy and pelvic radiation therapy compared with pelvic radiation therapy alone as adjuvant therapy after radical surgery in high-risk early-stage cancer of the cervix. *Obstet Gynecol Surv* 2000;55:491–492.

44. Sobin LH, Gospodarowicz MK Wittekind C. *TNM Classification of Malignant Tumours (7th edition)*. New York, USA: Wiley-Blackwell, 2009.
45. Takeshima N, Yanoh K, Tabata T, Nagai K, Hirai Y, Hasumi K. Assessment of the revised International Federation of Gynecology and Obstetrics staging for early invasive squamous cervical cancer. *Gynecol Oncol* 1999;74:165–169.
46. Lee KB, Lee JM, Park CY, Lee KB, Cho HY, Ha SY. Lymph node metastasis and lymph vascular space invasion in microinvasive squamous cell carcinoma of the uterine cervix. *Int J Gynecol Cancer* 2006;16:1184–1187.
47. Diab Y. Sentinel lymph nodes mapping in cervical cancer a comprehensive review. *Int J Gynecol Cancer* 2017;27:154–158.
48. Andikyan V, Khoury-Collado F, Denesopolis J, Park KJ, Hussein YR, Brown CL *et al*. Cervical conization and sentinel lymph node mapping in the treatment of stage I cervical cancer: is less enough? *Int J Gynecol Cancer* 2014;24:113–117.
49. Gortzak-Uzan L, Jimenez W, Nofech-Mozes S, Ismiil N, Khalifa M, Dubé V *et al*. Sentinel lymph node biopsy vs. pelvic lymphadenectomy in early stage cervical cancer: is it time to change the gold standard? *Gynecol Oncol* 2010;116:28–32.
50. Juretzka MM, Jensen KC, Longacre TA, Teng NN, Husain A. Detection of pelvic lymph node micrometastasis in stage IA2–IB2 cervical cancer by immunohistochemical analysis. *Gynecol Oncol* 2004;93:107–111.
51. Horn L-C, Hentschel B, Fischer U, Peter D, Bilek K. Detection of micrometastases in pelvic lymph nodes in patients with carcinoma of the cervix uteri using step sectioning: frequency, topographic distribution and prognostic impact. *Gynecol Oncol* 2008;111:276-281.
52. Cibula D, Abu-Rustum NR, Dusek L, Zikan M, Zaal A, Sevcik L *et al*. Prognostic significance of low volume sentinel lymph node disease in early-stage cervical cancer. *Gynecol Oncol* 2012;124:496–501.
53. Horn L-C, Hentschel B, Galle D, Bilek K. Extracapsular extension of pelvic lymph node metastases is of prognostic value in carcinoma of the cervix uteri. *Gynecol Oncol* 2008;108:63–67.
54. Metindir J, Bilir Dilek G. Evaluation of prognostic significance in extracapsular spread of pelvic lymph node metastasis in patients with cervical cancer. *Eur J Gynaecol Oncol* 2008;29:476–478.
55. Singh N, Rous B, Ganesan R. *2018 FIGO Staging System for Cervical Cancer: Summary and Comparison with 2009 FIGO Staging System*. Derby, UK: The British Association for Gynaecological Pathologists, 2019.
56. Alfsen GC, Kristensen GB, Skovlund E, Pettersen EO, Abeler VM. Histologic subtype has minor importance for overall survival in patients with adenocarcinoma of the uterine cervix: a population-based study of prognostic factors in 505 patients with nonsquamous cell carcinomas of the cervix. *Cancer* 2001;92:2471–2483.
57. Cho HC, Kim H, Cho HY, Kim K, No JH, Kim YB. Prognostic significance of perineural invasion in cervical cancer. *Int J Gynecol Pathol* 2013;32:228–233.

58. Burghardt E, Baker J, Tulusan AH, Haas J. Results of surgical treatment of 1028 cervical cancers studied with volumetry. *Cancer* 1992;70:648–655.
59. Roma AA, Mistretta TA, Diaz De Vivar A, Park KJ, Alvarado-Cabrero I, Rasty G *et al.* New pattern-based personalized risk stratification system for endocervical adenocarcinoma with important clinical implications and surgical outcome. *Gynecol Oncol* 2016;141:36–42.
60. Stolnicu S, Barsan I, Hoang L, Patel P, Terinte C, Pesci A *et al.* Stromal invasion pattern identifies patients at lowest risk of lymph node metastasis in HPV-associated endocervical adenocarcinomas, but is irrelevant in adenocarcinomas unassociated with HPV. *Gynecol Oncol* 2018;150:56–60.
61. Heatley MK. A comparison of three methods of orienting cervical punch biopsies. *J Clin Pathol* 1999;52:149–150.
62. Byrom J, Douce G, Jones P, Tucker H, Millinship J, Dhar K *et al.* Should punch biopsies be used when high-grade disease is suspected at initial colposcopic assessment? A prospective study. *Int J Gynecol Cancer* 2006;16:253–256.
63. Darragh TM, Colgan TJ, Cox JT, Heller DS, Henry MR, Luff RD *et al.* The Lower Anogenital Squamous Terminology Standardization project for HPV-associated lesions: background and consensus recommendations from the College of American Pathologists and the American Society for Colposcopy and Cervical Pathology. *Int J Gynecol Pathol* 2013;32:76–115.
64. Kalof AN, Cooper K. p16INK4a immunoexpression: surrogate marker of high-risk HPV and high-grade cervical intraepithelial neoplasia. *Adv Anat Pathol* 2006;13:190–194.
65. Cameron RI, Maxwell P, Jenkins D, McCluggage WG. Immunohistochemical staining with MIB1, bcl2 and p16 assists in the distinction of cervical glandular intraepithelial neoplasia from tubo-endometrial metaplasia, endometriosis and microglandular hyperplasia. *Histopathology* 2002;41:313–321.
66. The British Association of Gynaecological Pathologists. *BAGP P16 Interpretation Guide*. Accessed March 2021. Available at: www.thebagp.org/download/bagp-ukneqas-c1qc-project-interpretation-guide-2018/
67. McCluggage WG, Sumathi VP, McBride HA, Patterson A. A panel of immunohistochemical stains, including carcinoembryonic antigen, vimentin, and estrogen receptor, aids the distinction between primary endometrial and endocervical adenocarcinomas. *Int J Gynecol Pathol* 2002;21:11–15.
68. McCluggage WG. Endocervical glandular lesions: controversial aspects and ancillary techniques. *J Clin Pathol* 2003;56:164–173.
69. Carleton C, Hoang L, Sah S, Kiyokawa T, Karamurzin YS, Talia KL *et al.* A detailed immunohistochemical analysis of a large series of cervical and vaginal gastric-type adenocarcinomas. *Am J Surg Pathol* 2016;40:636–644.
70. Howitt BE, Emori MM, Drapkin R, Gaspar C, Barletta JA, Nucci MR *et al.* GATA3 is a sensitive and specific marker of benign and malignant mesonephric lesions in the lower female genital tract. *Am J Surg Pathol* 2015;39:1411–1419.

71. Kenny SL, McBride HA, Jamison J, McCluggage WG. Mesonephric adenocarcinomas of the uterine cervix and corpus: HPV-negative neoplasms that are commonly PAX8, CA125, and HMGA2 positive and that may be immunoreactive with TTF1 and hepatocyte nuclear factor 1-beta. *Am J Surg Pathol* 2012;36:799–807.
72. McCluggage WG, Kennedy K, Busam KJ. An immunohistochemical study of cervical neuroendocrine carcinomas: neoplasms that are commonly TTF1 positive and which may express CK20 and P63. *Am J Surg Pathol* 2010;34:525–532.
73. McCluggage WG. Immunohistochemistry as a diagnostic aid in cervical pathology. *Pathology* 2007;39:97–111.
74. Public Health England. *NHS Cervical Screening Programme. Colposcopy and Programme Management (3rd edition). NHSCSP Publication Number 20*. Accessed March 2016. Available at: [https://www.bsccp.org.uk/assets/file/uploads/resources/NHSCSP_20_Colposcopy_and_Programme_Management_\(3rd_Edition\)_2\).pdf](https://www.bsccp.org.uk/assets/file/uploads/resources/NHSCSP_20_Colposcopy_and_Programme_Management_(3rd_Edition)_2).pdf)

Appendix A **TNM and FIGO pathological staging of cervical carcinoma: including summary of changes⁵⁵**

FIGO cervical cancer staging (2018)

Stage I	The carcinoma is strictly confined to the cervix (extension to the corpus would be disregarded)
Stage IA	Invasive carcinoma that can be diagnosed only by microscopy with measured deepest invasion ≤ 5 mm <ul style="list-style-type: none">• stage IA1: measured stromal invasion ≤ 3.0 mm• stage IA2: measured stromal invasion >3.0 mm and ≤ 5.0 mm
Stage IB	Invasive carcinoma with measured deepest invasion >5 mm, limited to the cervix with size measured by maximum tumour diameter* <ul style="list-style-type: none">• stage IB1: invasive carcinoma >5.0 mm depth of invasion and <2 cm in greatest dimension• stage IB2: invasive carcinoma >2 cm and <4 cm in greatest dimension• stage IB3: invasive carcinoma >4 cm in greatest dimension
Stage II	Cervical carcinoma invades beyond the uterus, but not to the pelvic sidewall or to the lower third of the vagina
Stage IIA	Without parametrial invasion <ul style="list-style-type: none">• stage IIA1: invasive carcinoma <4 cm in greatest dimension• stage IIA2: invasive carcinoma >4 cm in greatest dimension
Stage IIB	With parametrial invasion
Stage III	The tumour extends to the pelvic wall and/or involves lower third of vagina and/or causes hydronephrosis or non-functioning kidney and/or involves pelvic and/or paraaortic nodes
Stage IIIA	Tumour involves lower third of the vagina, with no extension to the pelvic wall
Stage IIIB	Extension to the pelvic wall and/or hydronephrosis or non-functioning kidney
Stage IIIC	Involves pelvic and/or para-aortic lymph nodes, irrespective of tumour size and extent (adding notation of r [imaging] and p [pathology] to indicate the findings that are used to allocate to stage IIIC)** <ul style="list-style-type: none">• stage IIIC1: pelvic lymph node metastasis only• stage IIIC2: para-aortic lymph node metastasis
Stage IV	The carcinoma has extended beyond the true pelvis or has involved (biopsy proven) the mucosa of the bladder or rectum
Stage IVA	Spread of the growth to adjacent organs
Stage IVB	Spread to distant organs

Notes:

*The involvement of vascular/lymphatic spaces should not change the staging.

**Example: Notation of r = imaging and p = pathology, e.g. imaging indicating pelvic lymph node metastasis would be stage IIIC1r and by pathological findings would be stage IIIC1p.

When in doubt, the lower staging should be assigned.

Presence of ITCs and micrometastases do not move a case to stage III.

Omental metastases and inguinal lymph nodes indicate distant spread and would be staged as stage IVB.

TNM8 Cervical cancer staging (with FIGO 2018).

TNM category*	FIGO stage (2018)**	Definition
T1	I	Cervical carcinoma confined to the uterus (extension to the corpus should be disregarded)
T1a	IA	Invasive carcinoma, diagnosed only by microscopy, with deepest invasion ≤ 5.0 mm
T1a1	IA1	Measured stromal invasion < 3.0 mm
T1a2	IA2	Measured stromal invasion of ≥ 3.0 mm and < 5.0 mm
T1b	IB	Invasive carcinoma with measured stromal invasion ≥ 5 mm (greater than stage IA) limited to the cervix uteri
T1b1	IB1	Invasive carcinoma with measured stromal invasion ≥ 5 mm and greatest dimension < 2 cm
T1b2	IB2	Invasive carcinoma with greatest dimension ≥ 2 cm and < 4 cm
T1b2	IB3	Invasive carcinoma with greatest dimension > 4 cm
T2	II	Cervical carcinoma invades beyond the uterus but not to the pelvic wall or to lower third of the vagina
T2a	IIA	Involvement limited to upper two-thirds of vagina without parametrial invasion
T2a1	IIA1	Invasive carcinoma < 4 cm in greatest dimension
T2a2	IIA2	Invasive carcinoma ≥ 4 cm in greatest dimension
T2b	IIB	With obvious parametrial invasion not extending to pelvic brim
T3	III	The tumour extends to the pelvic wall and/or involves lower third of the vagina, and/or causes hydronephrosis or non-functioning kidney and/or involves pelvic and/or para-aortic nodes***
T3a	IIIA	Tumour involves lower third of vagina, with no extension to the pelvic wall
T3b	IIIB	Extension to the pelvic wall and/or hydronephrosis or non-functioning kidney
T4	IV	The carcinoma has extended beyond the true pelvis or has involved (biopsy proven) the mucosa of the bladder or rectum. Bullous oedema, as such, does not permit a case to be allocated to stage IV
T4a	IVA	Spread of growth to adjacent organs

N*	IIIC	Involvement of pelvic and/or para-aortic lymph nodes, irrespective of tumour size and extent
	IIIC1	Pelvic lymph node metastasis only
	IIIC2	Para-aortic lymph node metastasis
M1	IVB	Spread to distant organs

Notes:

*TNM (8th edition) does not include classification for the new FIGO groups IB3, IIIC1, and IIIC2. TNM defines only regional lymph nodes, with N0 (i+) indicating isolated tumour cells in regional lymph node(s) no greater than 0.2 mm, and N1 indicating regional lymph node metastasis.

**When in doubt, lower staging should be assigned. Involvement of vascular/lymphatic spaces does not change staging.

***Adding notation of r (imaging) and p (pathology) to indicate the findings that are used to allocate the case to stage IIIC.

Summary of changes to FIGO staging

FIGO stage I (2018): Carcinoma strictly confined to the cervix (extension to the uterine corpus should be disregarded)

2009 FIGO stage: description	2018 FIGO stage: description	Comment
IA: Invasive carcinoma diagnosed only by microscopy, with maximum depth of invasion ≤ 5 mm and largest extension ≤ 7 mm	IA: Invasive carcinoma diagnosed only by microscopy, with maximum depth of invasion ≤ 5 mm	Lateral extent of the carcinoma is no longer considered in distinguishing between FIGO stage IA and IB carcinomas
<ul style="list-style-type: none"> IA1: measured stromal invasion < 3 mm in depth and extension ≤ 7 mm 	<ul style="list-style-type: none"> IA1: measured stromal invasion ≤ 3 mm in depth 	
<ul style="list-style-type: none"> IA2: measured stromal invasion ≥ 3 mm and < 5 mm in depth and extension ≤ 7 mm 	<ul style="list-style-type: none"> IA2: measured stromal invasion > 3 mm and ≤ 5 mm in depth 	
IB: Clinically visible lesions limited to the cervix or pre-clinical cancers greater than stage IA	IB: Invasive carcinoma with measured deepest invasion > 5 mm (greater than stage IA), lesion limited to the cervix uteri with size measured by maximum tumour diameter	<ul style="list-style-type: none"> See above Lymphovascular space invasion must be commented on, although does not affect FIGO stage
<ul style="list-style-type: none"> IB1: Clinically visible lesion ≤ 4.0 cm in greatest dimension 	<ul style="list-style-type: none"> IB1: Invasive carcinoma > 5 mm depth of stromal invasion, and ≤ 2 cm in greatest dimension 	New stage category
	<ul style="list-style-type: none"> IB2: Invasive carcinoma > 2 cm and ≤ 4 cm in greatest dimension 	New stage category

<ul style="list-style-type: none"> • IB2: Invasive carcinoma >4 cm in greatest dimension 	<ul style="list-style-type: none"> • IB3: Invasive carcinoma >4 cm in greatest dimension 	New stage category
--	--	--------------------

FIGO stage II (2018): Carcinoma invades beyond the uterus, but has not extended onto the lower third of the vagina or to the pelvic wall

2009 FIGO stage: description	2018 FIGO stage: description	Comment
IIA: Without parametrial invasion	IIA: Involvement limited to the upper two-thirds of the vagina without parametrial invasion	No major change
<ul style="list-style-type: none"> • IIA1: Clinically visible lesion ≤4 cm in greatest dimension 	<ul style="list-style-type: none"> • IIA1: Invasive carcinoma ≤4cm in greatest dimension 	
<ul style="list-style-type: none"> • IIA2: Clinically visible lesion >4 cm in greatest dimension 	<ul style="list-style-type: none"> • IIA2: Invasive carcinoma >4 cm in greatest dimension 	
IIB: With obvious parametrial invasion	IIB: With parametrial involvement but not up to the pelvic wall	No change

FIGO stage III (2018): Carcinoma involves the lower third of the vagina and/or extends to the pelvic wall and/or causes hydronephrosis or non-functioning kidney and/or involves pelvic and/or para-aortic lymph nodes

2009 FIGO stage: description	2018 FIGO stage: description	Comment
IIIA: Tumour involves lower third of the vagina, with no extension to the pelvic wall	IIIA: Carcinoma involves the lower third of the vagina with no extension to the pelvic wall	No change
IIIB: Extension to the pelvic wall and/or hydronephrosis or non-functioning kidney	IIIB: Extension to the pelvic wall and and/or causes hydronephrosis or non-functioning kidney	No change
	IIIC: Involvement of pelvic and/or para-aortic lymph nodes, irrespective of tumour size and extent (with r and p notations)*	New stage category
	<ul style="list-style-type: none"> • IIIC1: Pelvic lymph node metastasis only 	New stage category
	<ul style="list-style-type: none"> • IIIC2: Para-aortic lymph node metastasis 	New stage category

*Adding notation of r (imaging) and p (pathology) to indicate the findings that are used to allocate the case to Stage IIIC.

Example: If imaging indicates pelvic lymph node metastasis, the stage allocation would be IIIC1r, and if confirmed by pathology, it would be IIIC1p.

The type of imaging modality or pathology technique should always be documented.

Stage IV (2018): Carcinoma has extended beyond the true pelvis or has involved (biopsy-proven) the mucosa of the bladder or rectum. (A bullous oedema, as such, does not permit a case to be allotted to Stage IV).

2009 FIGO stage: description	2018 FIGO stage: description	Comment
IVA: Spread of the growth to adjacent organs	IVA: Spread to adjacent pelvic organs	No change
IVB: Spread to distant organs	IVB: Spread to distant organs	No change

Appendix B WHO classification of cervical epithelial tumours and SNOMED-CT coding (modified from WHO Classification of tumour of the uterine cervix)

Morphological codes	SNOMED 2/3 /ICD-O code	SNOMED-CT terminology	SNOMED-CT code
Squamous epithelial tumours			
Squamous intraepithelial lesions			
Low-grade squamous intraepithelial lesion (Cervical intraepithelial neoplasia, grade 1)	M-80770	Squamous intraepithelial neoplasia, low grade (morphologic abnormality)	450595003
High-grade squamous intraepithelial lesion (Cervical intraepithelial neoplasia, grade 2) (Cervical intraepithelial neoplasia, grade 3)	M-80772	Squamous intraepithelial neoplasia, grade III (morphologic abnormality)	20365006
Squamous cell carcinoma, HPV-associated	M-80853	Squamous cell carcinoma, no International Classification of Diseases for Oncology subtype (morphologic abnormality)	28899001
Squamous cell carcinoma, HPV-independent	M-80863	Squamous cell carcinoma, keratinizing (morphologic abnormality)	18048008
Squamous cell carcinoma, NOS	M-80703	Squamous cell carcinoma, large cell, non-keratinizing (morphologic abnormality)	45490001

Morphological codes	SNOMED 2/3 /ICD-O code	SNOMED-CT terminology	SNOMED-CT code
Adenocarcinoma, HPV-associated	M84833	Adenocarcinoma, no subtype (morphologic abnormality)	35917007
Adenocarcinoma, HPV-independent, astric type	M-84823	Mucinous adenocarcinoma, endocervical type (morphologic abnormality)	128695008
Adenocarcinoma, HPV-independent, clear cell type	M-83103	Clear cell adenocarcinoma (morphologic abnormality)	30546008
Adenocarcinoma, HPV-independent, mesonephric type	M-91103	Mesonephroma, malignant (morphologic abnormality)	2221008
Endometrioid carcinoma NOS	M-83803	Endometrioid carcinoma (morphologic abnormality)	30289006
Carcinosarcoma NOS	M-89803	Carcinosarcoma (morphologic abnormality)	63264007
Adenosquamous carcinoma	M-85603	Adenosquamous carcinoma (morphologic abnormality)	59367005
Mucoepidermoid carcinoma	M-84303	Mucoepidermoid carcinoma (morphologic abnormality)	4079000
Adenoid basal carcinoma	M-80983	Adenoid basal carcinoma (morphologic abnormality)	128637002
Carcinoma, undifferentiated, NOS	M-80203	Carcinoma, undifferentiated (morphologic abnormality)	38549000

Mixed epithelial and mesenchymal tumours

Morphological codes	SNOMED 2/3 /ICD-O code	SNOMED-CT terminology	SNOMED-CT code
Adenomyoma NOS Mesonephric-type adenomyoma Endocervical-type adenomyoma	M-89320	Adenomyoma (morphologic abnormality)	40293003
Adenosarcoma	M-89333	Adenosarcoma (morphologic abnormality)	31470003

Appendix C Reporting proforma for cervical cancer in excisional cervical biopsies

Surname: Forenames: Date of birth:
 Patient identifier (CHI/NHS no):..... Hospital:..... Hospital no:
 Date of surgery: Date of receipt:..... Date of reporting:
 Report no: Pathologist: Surgeon:

Description of specimen and core macroscopic items

Wedge Cone Loop Biopsy of cervix:.....mm xmm and mm thick/deep
 Number of fragments received, measurement of each and block designation:

Core microscopic items

Invasive malignancy:

Type: HPV associated HPV independent
 Category: Squamous cell carcinoma Adenosquamous carcinoma Adenocarcinoma
 Neuroendocrine carcinoma Other (specify.....)

Differentiation/grade:

Well/grade 1 Moderate/grade 2 Poor/grade 3 Not assessable/GX N/A

Distribution of invasive component: Unifocal Multifocal

Tumour size: Maximum thickness/depth of invasion (delete as appropriate)mm
 Maximum horizontal dimension in one slicemm

Are invasive foci present in three or more sequential slices of tissue: Yes No

Excision status

Margin	Not involved (distance)	Involved	Not assessable
Ectocervical			
Endocervical			
Deep radial			

Other features:

CIN (cervical intra-epithelial neoplasia) grade: CIN 1 CIN 2 CIN 3 Absent

CGIN (cervical glandular intraepithelial neoplasia) : Present Absent

CGIN type: HPV associated HPV independent

SMILE (stratified mucin-producing intra-epithelial lesion): Present Absent

Excision margins: (specify whether involved by CIN, CGIN and/or SMILE)

Ectocervical resection margin: Clear Involved by CIN CGIN SMILE Not assessable

Endocervical resection margin: Clear Involved by CIN CGIN SMILE Not assessable

Deep lateral/radial resection margin: Clear Involved by CIN CGIN SMILE Not assessable

Lymphovascular space invasion: Present Absent

Provisional pathological FIGO stage 2018

SNOMED codes: T..... M.....

Signature of pathologist: Date.....

Note: In an excisional specimen with invasive cancer, this should be the only proforma on the report.

Appendix D Reporting proforma for cervical cancer in hysterectomy specimens

Surname: Forenames: Date of birth:
Patient identifier (CHI/NHS no):..... Hospital: Hospital no:
Date of surgery: Date of receipt:..... Date of reporting:
.....
Report no: Pathologist: Surgeon:

Description of specimen and core macroscopic items

Dimensions of uterus: Length.....mm Transverse.....mm Anteroposterior.....mm
Vaginal cuff: Present Absent Length.....mm Diameter.....mm
Adnexa: Present Absent
Normal Abnormal (specify).....
Cervix:
No tumour seen Maximum dimension of tumour:mm
Position of cervical tumour: Anterior Posterior Right Left Circumferential
Ectocervix Endocervix
Macroscopic involvement of vagina: Yes No
Macroscopic involvement of parametria: Yes No

Core microscopic items

Type: HPV associated HPV independent
Category: Squamous cell carcinoma Adenosquamous carcinoma Adenocarcinoma
Neuroendocrine carcinoma Other (specify).....
Differentiation/grade: Well/grade 1 Moderate/grade 2 Poor/grade 3
Not assessable/GX Not applicable
Tumour size: Maximum horizontal dimension.....mm
Thickness/depth of invasion (delete as appropriate).....mm
Minimum thickness of uninvolved cervical stroma (minimum tumour-free rim):.....mm
Position of this:.....
Closest radial resection margin (include parametrial tissue thickness):.....mm
Position of this:.....
Vaginal involvement: Yes No Distance from distal vaginal epithelial margin:.....mm
Position of this:.....
Parametrial involvement: Yes No If involved: Left Right
Lymphovascular invasion: Yes No
CIN grade: CIN 1 CIN 2 CIN 3 Absent
CGIN grade: Present Absent

CGIN type: HPV associated HPV independent

SMILE: Present Absent

Sentinel nodes: Number of nodes sampled:..... Number of nodes involved:.....
If involved, size of largest deposit.....mm

Extranodal spread: Yes No

Pelvic nodes: (pelvic group includes obturator, internal, external and common iliac nodes)

	Right	Left
Total number		
Number involved		

Extranodal spread: Yes No

Para-aortic nodes: Positive Negative Not sampled

Total number of nodes Number of positive nodes

Extranodal spread: Yes No

Other tissues and organs	Normal	Abnormal (describe)
Endometrium	<input type="checkbox"/>	<input type="checkbox"/>
Myometrium	<input type="checkbox"/>	<input type="checkbox"/>
Right adnexum	<input type="checkbox"/>	<input type="checkbox"/>
Left adnexum	<input type="checkbox"/>	<input type="checkbox"/>

Dimensions of invasive carcinoma in previous biopsy/loop (if available):mm xmm

Vascular invasion in previous biopsy/loop (if available):.....

Provisional pathological FIGO stage 2018

(Please r = imaging and p = pathology, when stage allocation is based on radiological or pathological findings)

Final staging may follow MDT review

SNOMED codes: T.....M.....
T.....M.....

Signature of pathologist: **Date**.....

Appendix E Reporting proforma for cervical cancer in excisional cervical biopsies in list format

Element name	Values	Implementation notes	COSD v8	COSD v9
Biopsy type	Single selection value list: <ul style="list-style-type: none"> • Wedge • Cone • Loop 		CR0760 Wedge = (BU) Biopsy NOS Cone = (BU) Biopsy NOS Loop = (EX) Excision	pCR0760 Wedge = (BU) Biopsy NOS Cone = (BU) Biopsy NOS Loop = (EX) Excision
Tumour dimension, horizontal (largest)	Size in mm		pCR0830* *Choose largest measurement	pCR0830* *Choose largest measurement
Tumour dimension, depth/thickness	Size in mm			
Number of fragments received	Integer			
Measurement, fragment 1	Size in mm			
Block designation, fragment 1	Free text			
Measurement, fragment n	Size in mm			
Block designation, fragment n	Free text			
Tumour type	Single selection value list: <ul style="list-style-type: none"> • Squamous cell carcinoma • Adenosquamous carcinoma • Adenocarcinoma • Neuroendocrine carcinoma • Other (specify) 			
Tumour type, other specify	Free text	Only applicable if 'Tumour type, other specify' is selected.		

Differentiation/grade	Single selection value list: <ul style="list-style-type: none"> Well/grade 1 Moderate/grade 2 Poor/grade 3 Not assessable/GX Not applicable 		CR0860 Well/grade 1 = (G1) Well differentiated Moderate/grade 2 = (G2) Moderately differentiated Poor/grade 3 = (G3) Poorly differentiated Not assessable/GX = (GX) Grade of differentiation is not appropriate or cannot be assessed	pCR0860 Well/grade 1 = (G1) Well differentiated Moderate/grade 2 = (G2) Moderately differentiated Poor/grade 3 = (G3) Poorly differentiated Not assessable/GX = (GX) Grade of differentiation is not appropriate or cannot be assessed
Distribution of invasive component	Single selection value list: <ul style="list-style-type: none"> Unifocal Multifocal 			
Tumour size, maximum thickness/depth of invasion	Size in mm		Does not exist in COSD v8	pGY7450
Tumour size, maximum horizontal direction in one slice	Size in mm			
Presence of invasive foci in three of more sequential slices of tissue	Single selection value list: <ul style="list-style-type: none"> Yes No 			
Excision status	Single selection value list: <ul style="list-style-type: none"> Incomplete Complete Not assessable 		CR0880 Incomplete = (05) Tumour reaches excision margin Complete = (01) Excision margins are clear (distance from margin not stated) Not assessable = (98) Not applicable	pCR0880 Incomplete = (05) Tumour reaches excision margin Complete = (01) Excision margins are clear (distance from margin not stated) Not assessable = (98) Not applicable

Distance to closest resection margin	Size in mm	Only applicable if 'Excision status, complete' is selected.		
Resection margin	Single selection value list: <ul style="list-style-type: none"> Ectocervical Endocervical Deep radial 			
Cervical intraepithelial neoplasia (CIN), grade	Single selection value list: <ul style="list-style-type: none"> CIN 1 CIN 2 CIN 3 Absent 		GY7300 CIN 1 = (1) Grade 1 CIN 2 = (2) Grade 2 CIN 3 = (3) Grade 3 Absent = (4) Not present Not selected = (X) Not assessable	pGY7300 CIN 1 = (1) Grade 1 CIN 2 = (2) Grade 2 CIN 3 = (3) Grade 3 Absent = (4) Not present Not selected = (X) Not assessable
Cervical glandular intraepithelial neoplasia (CGIN)	Single selection value list: <ul style="list-style-type: none"> Present Absent 		GY7290 Present = (2) High Absent = (3) Not present Not selected = (X) Not assessable	pGY7290 Present = (2) High Absent = (3) Not present Not selected = (X) Not assessable
CGIN type	Single selection value list: <ul style="list-style-type: none"> HPV associated HPV independent 			
Stratified mucin-producing intraepithelial lesion (SMILE)	Single selection value list: <ul style="list-style-type: none"> Present Absent 		GY7350 Present = (1) Present Absent = (2) Absent Not selected = (X) Not assessable	pGY7350 Present = (1) Present Absent = (2) Absent Not selected = (X) Not assessable

Ectocervical resection margin	Multiple selection value list: <ul style="list-style-type: none"> • Clear • Involved by CIN • Involved by CGIN • Involved by SMILE • Not assessable 	** - Select worst based on following priority – Y, N, X	GY7310** Clear = (N) No Involved by CIN = (Y) Yes Involved by CGIN = (Y) Yes Involved by SMILE = (Y) Yes Not assessable = (X) Not assessable Not selected = (N) No	pGY7310** Clear = (N) No Involved by CIN = (Y) Yes Involved by CGIN = (Y) Yes Involved by SMILE = (Y) Yes Not assessable = (X) Not assessable Not selected = (N) No
Endocervical resection margin	Multiple selection value list: <ul style="list-style-type: none"> • Clear • Involved by CIN • Involved by CGIN • Involved by SMILE • Not assessable 			
Deep lateral/radial resection margin	Multiple selection value list: <ul style="list-style-type: none"> • Clear • Involved by CIN • Involved by CGIN • Involved by SMILE • Not assessable 			
Lymphovascular space invasion	Single selection value list: <ul style="list-style-type: none"> • Present • Absent 		pCR0870 Present = (YU) Yes – vascular/lymphatic invasion present Absent = (NU) No – vascular/lymphatic invasion not present Not selected = (99) Not known	pCR0870 Present = (YU) Yes – vascular/lymphatic invasion present Absent = (NU) No – vascular/lymphatic invasion not present Not selected = (99) Not known

Provisional FIGO stage 2018	Single selection value list: <ul style="list-style-type: none"> • IA1 • IA2 • IB1 • IB2 • IB3 • IIA1 • IIA2 • IIB • IIIA • IIIB • IIIC1 • IIIC2 • IVA • IVB 			
SNOMED T code	May have multiple codes. Look up from SNOMED tables.		CR6410	pCR6410
SNOMED M code	May have multiple codes. Look up from SNOMED tables.		CR6420	pCR6420

Appendix F

Reporting proforma for cervical cancer in hysterectomy specimens in list format

Element name	Values	Implementation notes	COSD v8	COSD v9
Dimensions of uterus, length	Size in mm			
Dimensions of uterus, transverse	Size in mm			
Dimensions of uterus, anteroposterior	Size in mm			
Vaginal cuff	Single selection value list: <ul style="list-style-type: none"> • Present • Absent 			
Vaginal cuff, length	Size in mm	Only applicable if 'Vaginal cuff, present' is selected.		
Vaginal cuff, diameter	Size in mm	Only applicable if 'Vaginal cuff, present' is selected.		
Adnexa	Single selection value list: <ul style="list-style-type: none"> • Present • Absent 			
Adnexa, present	Single selection value list: <ul style="list-style-type: none"> • Normal • Abnormal 	Only applicable if 'Adnexa, present' is selected.		
Adnexa, present, abnormal specify	Free text	Only applicable if 'Adnexa, present, abnormal' is selected.		
Cervical tumour	Single selection value list: <ul style="list-style-type: none"> • No tumour seen 			
Maximum dimensions of cervical tumour, dimension: largest horizontal dimension	Size in mm		pCR0830* *Choose largest	pCR0830* *Choose largest

Maximum dimensions of cervical tumour, dimension: depth of invasion/tumour thickness	Size in mm		measurement	measurement
Position of cervical tumour	<p>Multiples selection value list:</p> <ul style="list-style-type: none"> • Anterior • Posterior • Right • Left • Circumferential • Ectocervix • Endocervix 			
Macroscopic involvement of vagina	<p>Single selection value list:</p> <ul style="list-style-type: none"> • Yes • No 			
Macroscopic involvement of parametria	<p>Single selection value list:</p> <ul style="list-style-type: none"> • Yes • No 			
Tumour type	<p>Single selection value list:</p> <ul style="list-style-type: none"> • HPV associated • HPV independent 			
Tumour category	<p>Single selection value list:</p> <ul style="list-style-type: none"> • Squamous cell carcinoma • Adenosquamous carcinoma • Adenocarcinoma • Neuroendocrine carcinoma • Other (specify) 			
Tumour category, other specify	Free text	Only applicable if 'Tumour category, other specify' is selected.		

Differentiation/grade	Single selection value list: <ul style="list-style-type: none"> Well/grade 1 Moderate/grade 2 Poor/grade 3 Not assessable/GX Not applicable 		CR0860 Well/grade 1 = (G1) Well differentiated Moderate/grade 2 = (G2) Moderately differentiated Poor/grade 3 = (G3) Poorly differentiated Not assessable/GX = (GX) Grade of differentiation is not appropriate or cannot be assessed	pCR0860 Well/grade 1 = (G1) Well differentiated Moderate/grade 2 = (G2) Moderately differentiated Poor/grade 3 = (G3) Poorly differentiated Not assessable/GX = (GX) Grade of differentiation is not appropriate or cannot be assessed
Tumour size, maximum horizontal dimension	Size in mm			
Tumour size, maximum thickness/depth of invasion	Size in mm		Does not exist in COSD v8	pGY7450
Minimum thickness of uninvolved cervical stroma	Size in mm		GY7360	pGY7360
Minimum thickness of uninvolved cervical stroma, position	Free text			
Closest radial resection margin	Size in mm			
Closest radial resection margin, position	Free text			
Vaginal involvement	Single selection value list: <ul style="list-style-type: none"> Yes No 		GY7370 Yes = (Y) Yes No = (N) No Not selected = (X) Not assessable	pGY7370 Yes = (Y) Yes No = (N) No Not selected = (X) Not assessable
Position of vaginal epithelial margin	Free text			
Distance from distal vaginal epithelial margin	Size in mm			
Parametrial involvement	Single selection value list:	***Select worst between paracervical and	GY7340***	pGY7340***

	<ul style="list-style-type: none"> • Yes • No 	parametrial involvement based on following priority – Y,N,X	Yes = (Y) Yes No = (N) No Not selected = (X) Not assessable	Yes = (Y) Yes No = (N) No Not selected = (X) Not assessable
Parametrial involvement, laterality	Single selection value list: <ul style="list-style-type: none"> • Left • Right 	Only applicable if 'Parametrial involvement, yes' is selected.		
Lymphovascular invasion	Single selection value list: <ul style="list-style-type: none"> • Yes • No 		pCR0870 Present = (YU) Yes – vascular/lymphatic invasion present Absent = (NU) No – vascular/lymphatic invasion not present Not selected = (99) Not known	pCR0870 Present = (YU) Yes – vascular/lymphatic invasion present Absent = (NU) No – vascular/lymphatic invasion not present Not selected = (99) Not known
Cervical intraepithelial neoplasia (CIN), grade	Single selection value list: <ul style="list-style-type: none"> • CIN 1 • CIN 2 • CIN 3 • Absent 		GY7300 CIN 1 = (1) Grade 1 CIN 2 = (2) Grade 2 CIN 3 = (3) Grade 3 Absent = (4) Not present Not selected = (X) Not assessable	pGY7300 CIN 1 = (1) Grade 1 CIN 2 = (2) Grade 2 CIN 3 = (3) Grade 3 Absent = (4) Not present Not selected = (X) Not assessable
Cervical glandular intraepithelial neoplasia (CGIN), grade	Single selection value list: <ul style="list-style-type: none"> • Present • Absent 		GY7290 Present = (2) High Absent = (3) Not present Not selected = (X) Not assessable	pGY7290 Present = (2) High Absent = (3) Not present Not selected = (X) Not assessable
CGIN type	Single selection value list: <ul style="list-style-type: none"> • HPV associated • HPV independent 			

Stratified mucin-producing intraepithelial lesion (SMILE)	Single selection value list: <ul style="list-style-type: none"> • Present • Absent 		GY7350 Present = (1) Present Absent = (2) Absent Not selected = (X) Not assessable	pGY7350 Present = (1) Present Absent = (2) Absent Not selected = (X) Not assessable
Number of sentinel nodes sampled	Integer	If no value is entered this indicates sentinel nodes were not submitted.		
Number of sentinel nodes involved	Integer			
Size of largest sentinel node deposit	Size in mm	Only applicable if 'Number of sentinel nodes involved' is >0.		
Sentinel node extranodal spread	Single selection value list: <ul style="list-style-type: none"> • Yes • No 	Only applicable if 'Number of sentinel nodes involved' is >0.		
Total number of pelvic nodes, right	Integer			
Number of involved pelvic nodes, right	Integer			
Total number of pelvic nodes, left	Integer			
Number of involved pelvic nodes, left	Integer			
Pelvic nodes, extranodal spread	Single selection value list: <ul style="list-style-type: none"> • Yes • No 	****Select worst between pelvic and para-aortic node extranodal spread based on following priority – Y,N,X	GY7230**** Yes = (Y) Yes No = (N) No Not selected = (X) Not assessable	pGY7230**** Yes = (Y) Yes No = (N) No Not selected = (X) Not assessable
Para-aortic nodes	Single selection value list: <ul style="list-style-type: none"> • Positive • Negative • Not sampled 			
Total number of para-aortic nodes	Integer		GY7060	pGY7060
Number of involved para-aortic nodes	Integer		GY7080	pGY7080

Para-aortic nodes, extranodal spread	Single selection value list: <ul style="list-style-type: none"> • Yes • No 	****Select worst between pelvic and para-aortic node extranodal spread based on following priority – Y,N,X	GY7230**** Yes = (Y) Yes No = (N) No Not selected = (X) Not assessable	pGY7230**** Yes = (Y) Yes No = (N) No Not selected = (X) Not assessable
Endometrium	Single selection value list: <ul style="list-style-type: none"> • Normal • Abnormal 			
Endometrium, abnormal, describe	Free text	Only applicable if 'Endometrium, abnormal' is selected.		
Myometrium	Single selection value list: <ul style="list-style-type: none"> • Normal • Abnormal 			
Myometrium, abnormal, describe	Free text	Only applicable if 'Myometrium, abnormal' is selected.		
Right adnexum	Single selection value list: <ul style="list-style-type: none"> • Normal • Abnormal 			
Right adnexum, abnormal, describe	Free text	Only applicable if 'Right adnexum, abnormal' is selected.		
Left adnexum	Single selection value list: <ul style="list-style-type: none"> • Normal • Abnormal 			
Left adnexum, abnormal, describe	Free text	Only applicable if 'Left adnexum, abnormal' is selected.		
Dimensions of invasive carcinoma in previous biopsy/loop, dimension 1: Maximum horizontal dimension	Size in mm			

Dimensions of invasive carcinoma in previous biopsy/loop, dimension 2: maximum invasive depth/tumour thickness	Size in mm			
Vascular invasion in previous biopsy/loop	Free text			
Provisional FIGO stage 2018	Single selection value list: <ul style="list-style-type: none"> • IA1 • IA2 • IB1 • IB2 • IB3 • IIA1 • IIA2 • IIB • IIIA • IIIB • IIIC1 • IIIC2 • IVA • IVB 			
SNOMED T code	May have multiple codes. Look up from SNOMED tables.		CR6410	pCR6410
SNOMED M code	May have multiple codes. Look up from SNOMED tables.		CR6420	pCR6420

Appendix G**Summary table – Explanation of grades of evidence**

(modified from Palmer K, Nairn M, Guideline Development Group. *BMJ* 2008;337:1832)

Grade (level) of evidence	Nature of evidence
Grade A	At least one high-quality meta-analysis, systematic review of randomised controlled trials or a randomised controlled trial with a very low risk of bias and directly attributable to the target cancer type or A body of evidence demonstrating consistency of results and comprising mainly well-conducted meta-analyses, systematic reviews of randomised controlled trials or randomised controlled trials with a low risk of bias, directly applicable to the target cancer type.
Grade B	A body of evidence demonstrating consistency of results and comprising mainly high-quality systematic reviews of case-control or cohort studies and high-quality case-control or cohort studies with a very low risk of confounding or bias and a high probability that the relation is causal and which are directly applicable to the target cancer type or Extrapolation evidence from studies described in A.
Grade C	A body of evidence demonstrating consistency of results and including well-conducted case-control or cohort studies and high-quality case-control or cohort studies with a low risk of confounding or bias and a moderate probability that the relation is causal and which are directly applicable to the target cancer type or Extrapolation evidence from studies described in B.
Grade D	Non-analytic studies such as case reports, case series or expert opinion or Extrapolation evidence from studies described in C.
Good practice point (GPP)	Recommended best practice based on the clinical experience of the authors of the writing group.

Appendix H AGREE II guideline monitoring sheet

The cancer datasets of the Royal College of Pathologists comply with the AGREE II standards for good quality clinical guidelines. The sections of this dataset that indicate compliance with each of the AGREE II standards are indicated in the table.

AGREE standard	Section of guideline
Scope and purpose	
1 The overall objective(s) of the guideline is (are) specifically described	Introduction
2 The health question(s) covered by the guideline is (are) specifically described	Introduction
3 The population (patients, public, etc.) to whom the guideline is meant to apply is specifically described	Foreword
Stakeholder involvement	
4 The guideline development group includes individuals from all the relevant professional groups	Foreword
5 The views and preferences of the target population (patients, public, etc.) have been sought	Foreword
6 The target users of the guideline are clearly defined	Introduction
Rigour of development	
7 Systematic methods were used to search for evidence	Foreword
8 The criteria for selecting the evidence are clearly described	Foreword
9 The strengths and limitations of the body of evidence are clearly described	Foreword
10 The methods for formulating the recommendations are clearly described	Foreword
11 The health benefits, side effects and risks have been considered in formulating the recommendations	Foreword and Introduction
12 There is an explicit link between the recommendations and the supporting evidence	1–9
13 The guideline has been externally reviewed by experts prior to its publication	Foreword
14 A procedure for updating the guideline is provided	Foreword
Clarity of presentation	
15 The recommendations are specific and unambiguous	1–9
16 The different options for management of the condition or health issue are clearly presented	1–9
17 Key recommendations are easily identifiable	1–9
Applicability	
18 The guideline describes facilitators and barriers to its application	Foreword
19 The guideline provides advice and/or tools on how the recommendations can be put into practice	Appendices A–G
20 The potential resource implications of applying the recommendations have been considered	Foreword
21 The guideline presents monitoring and/or auditing criteria	10
Editorial independence	
22 The views of the funding body have not influenced the content of the guideline	Foreword
23 Competing interest of guideline development group members have been recorded and addressed	Foreword