

OSPACE section 1 (~90 minutes)

Fifteen compulsory questions, typically 6 minutes per question (more complex questions can be allowed more time up to 10 minutes)

Ten example questions are listed below

1. Examine this Quality Control Chart (6 min)
 - a. What abnormality is shown in this quality control chart?
 - b. Which rule has been violated and how?
 - c. Give two possible scenarios which may account for this abnormality.

2. Examine these electron-micrographs (6 min)
 - a. In which clinical specimen type can you find all these viruses?
 - b. Name the viruses labelled A to G.
 - c. Which of these viruses belong to the same viral family? Name the family.
 - d. Which of these viruses have effective vaccines? What is the nature of this vaccine?

3. Examine this phylogenetic tree (6 min)
 - a. Does this phylogenetic tree support transmission of hepatitis C in the dialysis unit? Why do you say so and which patients were involved?
 - b. Can you determine which patient is the index case from this tree? Why do you say so?
 - c. What is the meaning of the number at the node of each branch?

4. Examine this set of laboratory data (6 min)
 - a. Interpret this set of laboratory data.
 - b. Give three possible explanations to account for this set of result?

5. These pictures are from different patients suffering different complications of the same viral infection (6 min)
 - a. Which virus caused these complications?
 - b. Name each complication.
 - c. Name four other possible complications of this viral infection?

6. This is the histological examination of brain tissue of a man died of an unexplained encephalopathy (6 min)
 - a. What is the diagnosis?

- b. What is the pathognomonic feature found in the histology slide?
- c. How do you diagnose this condition before death?

7. This is the brain MRI of a patient from sub-Saharan Africa who presented with a two week history of headache and admitted with generalised seizures (6 min)

- a. What is the most likely diagnosis?
- b. Name one possible alternative diagnosis.
- c. What is the most likely underlying condition?
- d. What is the management of this condition?

8. Examine these clinical pictures (6 min)

- a. Which two viral infections were demonstrated in these clinical pictures?
- b. Name the signs found in the oral cavity and match each one to its corresponding clinical picture.
- c. What laboratory methods are available to diagnose these two infections?

9. Examine these monolayer cell culture inoculated with respiratory sample from a patient (6 min)

- a. Describe the morphology of the cells.
- b. Describe the cytopathic effect observed
- c. What viruses could be growing in this cell monolayer with this cytopathic effect?

10. Examine this HIV protease and reverse transcriptase sequence and the report? (10 min)

- a. What mutations are shown?
- b. What are the clinical significances?
- c. Recommend a suitable treatment regimen for this patient.

OSPACE section 2 verbal questions (Total duration = 60 minutes)

Four compulsory verbal questions

(One minute to consider the case before examination, 10 minutes of verbal communication, 4 minutes to move to the next question)

Two examples given below:

Verbal Question 1:

A 46 year old woman with systemic lupus erythematosus presented to her GP with features compatible with ophthalmic shingles. She was on prednisolone and azathioprine and her creatinine clearance was 35 ml/min. GP started oral aciclovir 800mg five times per day. Three days later, she presented to A&E with confusion and was admitted. The medical registrar called you to discuss.

Verbal Question 2:

An orthopaedic surgeon sustained a penetrative injury from a sharp piece of bone when operating on a patient with multiple fractures following a road traffic accident. The source patient was thought to be an intravenous drug user. He remained unconscious after the operation and not expected to regain consciousness anytime soon. The injured surgeon called you for advice.

OSPACE section 2 – practical questions (total duration = 120 minutes)

Four compulsory questions – 30 minutes per question

One example is shown below:

Question 1

Part 1 (5 minutes)

You are asked to set up a multiplex real time PCR for influenza viruses.

- 1a.** List the basic reagents required in a real time PCR reaction.
- 1b.** Explain the mechanism of action of a dual-labelled probe in real time PCR.
- 1c.** What is SYBR Green and how can it be used in a PCR designed to detect two viral variants?

Return Answers to Part 1 before proceeding to Part 2

Part 2 (25 minutes)

A multiplex real time PCR run for influenza A and influenza B matrix targets and an internal control target is performed and the amplification curves are provided.

The run include throat/nasal swabs from the following 4 patients:

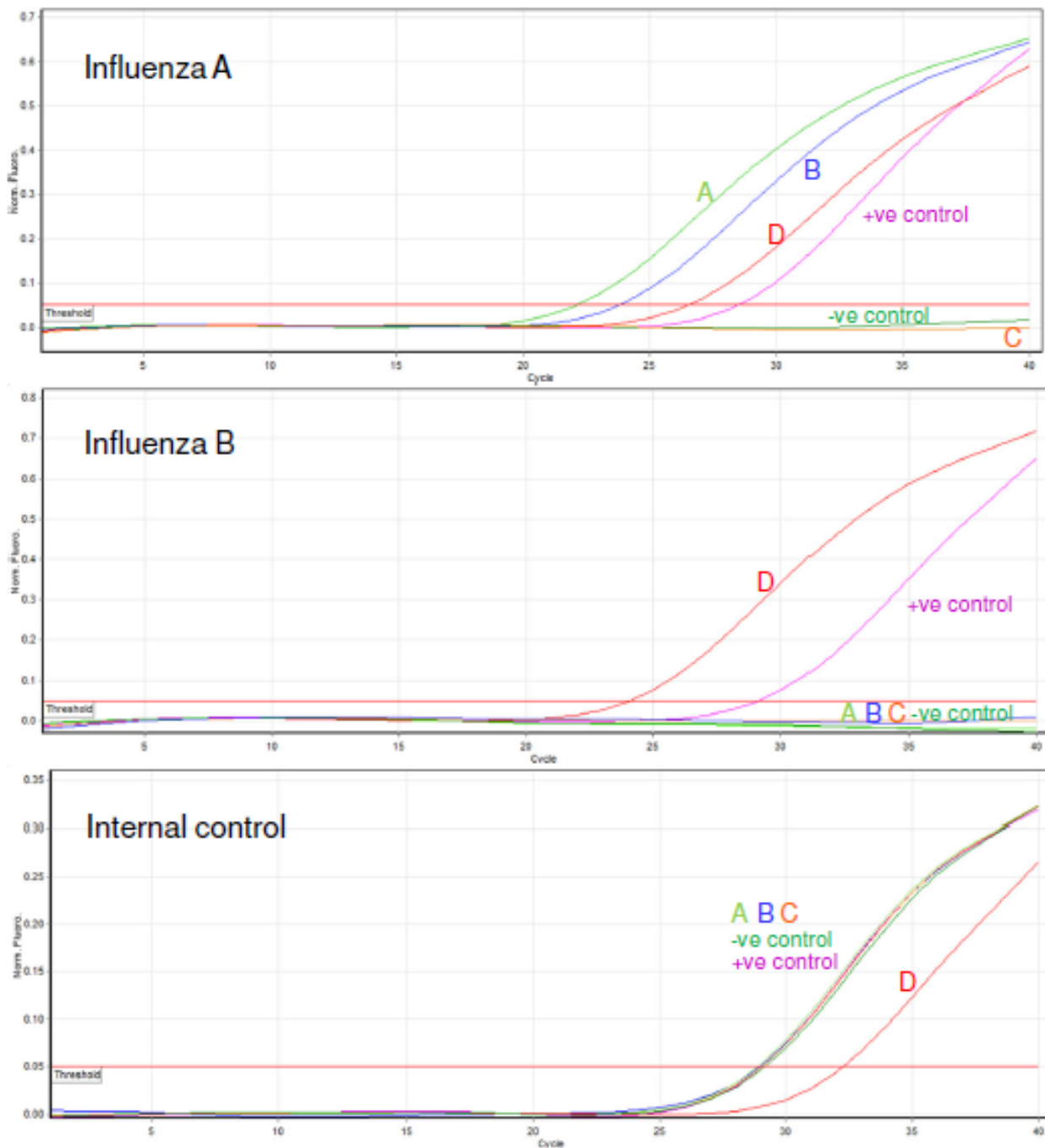
Patient A/Sample A – 52 year old man with lymphoma who has just completed chemotherapy and found to be in remission. Admitted to hospital with fever, cough and shortness of breath. Chest x-ray showed patchy consolidation.

Patient B/Sample B – 20 year old international student returned from China 2 days ago. Admitted to hospital with fever and flu like symptoms. ? atypical pneumonia.

Patient C/Sample C – 63 year old woman returned 2 days ago from a pilgrimage to Saudi Arabia. Developed high fever and was admitted to ITU with respiratory distress.

Patient D/Sample D – 4 year old boy previously healthy. Attended GP because of coryzal symptoms. Up to date with immunisation.

Amplification Plots:



1d. Analyse the results and provide a report for each sample. Please explain any anomalies.

1e. What further tests would you recommend on each sample?

1f. Provide management advice to the clinical team in each case.