

Mariia Ivanova<sup>1</sup>, Olena Dyadyk<sup>1</sup>, Dmytro Ivanov<sup>2</sup>

<sup>1</sup> Shupyk National Healthcare University of Ukraine, Pathology department (Kyiv, Ukraine)

<sup>2</sup> Shupyk National Healthcare University of Ukraine, Nephrology and RRT department (Kyiv, Ukraine)

# CASE OF PRIMARY DIAGNOSED SCLERODERMA BY RENAL BIOPSY

## Background

Scleroderma is a chronic multisystem disease with a various clinical presentation. The disease is associated with small arteries vasculopathy, but rarely manifests first with renal crisis and has no laboratory parameter to predict it (*Nat Rev Nephrol 2016;12:678*). The case describes scleroderma with renal crisis as primary onset, first diagnosed by renal biopsy (RB).

## Methods

26 year old female patient with no previous history of systemic or renal disease presented with acute onset of hypertension and proteinuria of 420 mg/mmol and the RB was performed.

## Results

RB revealed 25 glomeruli in total with various degree of sclerosis and cell proliferation, endothelial swelling, mesangiolytic, capillary loops collapse with thrombosis and fibrinoid necrosis (*Fig. 1*).

Interstitium was swollen with focal fibrosis and diffuse lymphohistiocytic inflammatory infiltration. Tubuli demonstrated pronounced degenerative changes with areas of dystrophy, atrophy and necrosis. The arteries presented pronounced sclerosis, fibrointimal thickening, endothelial swelling with mucoid changes, various degree of fibrinoid necrosis and thrombosis. Interlobular arteries demonstrated intimal hypercellularity and basement membrane duplication (“**onion-skin**” type) (*Fig. 1*).

Immunohistochemical assay resulted in weak immunoglobulin staining in glomeruli and moderate to strong immunoglobulin presence in tubuli and interstitium. C3 was weak and C1q was negative. CD20 demonstrated sporadic stromal lymphocytes. Fibrinogen staining was positive in thrombosis areas.

## Conclusions

Pathologic examination revealed chronic kidney damage of the secondary origin associated with systemic sclerosis (scleroderma).

**The diagnosis was further confirmed clinically.**

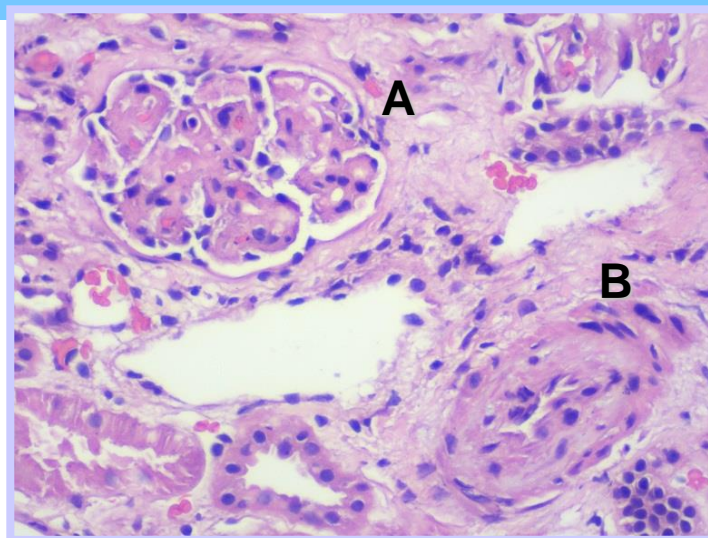


Figure 1. (A) Kidney glomerulus with marked endothelial swelling, mesangiolytic, capillary loops swelling with thrombosis; (B) Sclerotic artery with onion-skin type wall duplication. *Hematoxylin&Eosin, X400*