



## Standards and datasets for reporting cancers

### Dataset for histopathological reporting of carcinomas and borderline tumours of the ovaries, fallopian tubes and peritoneum

July 2019

**Authors:** Dr Nafisa Wilkinson, University College London Hospitals NHS Foundation Trust  
Dr Katherine Vroobel, The Royal Marsden NHS Foundation Trust  
Professor W Glenn McCluggage, Royal Group of Hospitals Trust

<b>Unique document number</b>	G079
<b>Document name</b>	Dataset for histopathological reporting of carcinomas of the ovaries, fallopian tubes and peritoneum
<b>Version number</b>	4
<b>Produced by</b>	Dr Nafisa Wilkinson, Dr Katherine Vroobel and Professor W Glenn McCluggage, on behalf of the College's Working Group on Cancer Services. All are specialist gynaecological pathologists and Dr Nafisa Wilkinson and Professor W Glenn McCluggage have published widely in this field.
<b>Date active</b>	July 2019 <b>(to be implemented within 3 months)</b>
<b>Date for review</b>	July 2022
<b>Comments</b>	<p>This document replaces the 3rd edition of <i>Datasets for the histopathological reporting of neoplasms of the ovaries and fallopian tubes and primary carcinomas of the peritoneum (3rd edition)</i> published in November 2010.</p> <p>In accordance with the College's pre-publications policy, this document was on the Royal College of Pathologists' website for consultation from 16 January to 13 February 2019. Responses and authors' comments are available to view on request, following final publication of this dataset.</p> <p><b>Dr Brian Rous</b> <b>Clinical Lead for Guideline Review (Cellular Pathology)</b></p>

The Royal College of Pathologists  
6 Alie Street, London E1 8QT  
Tel: 020 7451 6700  
Fax: 020 7451 6701  
Web: [www.rcpath.org](http://www.rcpath.org)

Registered charity in England and Wales, no. 261035  
© 2019, The Royal College of Pathologists

This work is copyright. You may download, display, print and reproduce this document for your personal, non-commercial use. All other rights reserved. Requests and inquiries concerning reproduction and rights should be addressed to the Royal College of Pathologists at the above address. First published: 2019.



## Contents

Foreword.....	3
1 Introduction.....	4
2 Specimen request form .....	5
3 Preparation of the specimen before dissection .....	7
4 Specimen handling and block selection: data items.....	8
5 Specimen handling and block selection: a guide.....	9
6 Microscopic description .....	11
7 Diagnostic coding and staging.....	16
8 Reporting of small biopsy specimens.....	17
9 Criteria for audit.....	17
10 References.....	18
Appendix A WHO classification and SNOMED ‘M’ coding of surface epithelial neoplasms .....	23
Appendix B TNM and FIGO classification of tumours of the ovary and fallopian tube, and primary peritoneal carcinomas .....	25
Appendix C Guide to use of immunohistochemistry in tubo-ovarian carcinomas .....	27
Appendix D Reporting proforma for ovarian, tubal and primary peritoneal carcinomas .....	29
Appendix E Reporting proforma for ovarian, tubal and primary peritoneal borderline tumours .....	32
Appendix F Reporting proforma for ovarian, tubal and primary peritoneal carcinomas in list format.....	35
Appendix G Reporting proforma for ovarian, tubal and primary peritoneal borderline tumours in list format.....	42
Appendix H Summary table – Explanation of grades of evidence .....	49
Appendix I AGREE II guideline monitoring sheet.....	50



NICE has accredited the process used by the Royal College of Pathologists to produce its cancer datasets. Accreditation is valid for five years from 25 July 2017. More information on accreditation can be viewed at [www.nice.org.uk/accreditation](http://www.nice.org.uk/accreditation). For full details on our accreditation visit: [www.nice.org.uk/accreditation](http://www.nice.org.uk/accreditation).

## Foreword

The cancer datasets published by the Royal College of Pathologists (RCPATH) are a combination of textual guidance, educational information and reporting proformas. The datasets enable pathologists to grade and stage cancers in an accurate, consistent manner in compliance with international standards and provide prognostic information, thereby allowing clinicians to provide a high standard of care for patients and appropriate management for specific clinical circumstances. This guideline has been developed to cover most common circumstances. However, we recognise that guidelines cannot anticipate every pathological specimen type and clinical scenario. Occasional variation from the practice recommended in this guideline may therefore be required to report a specimen in a way that maximises benefit to the patient.

Each dataset contains core data items (see Appendices D–G) that are mandated for inclusion in the Cancer Outcomes and Services Dataset (COSD – previously the National Cancer Data Set) in England. Core data items are items that are supported by robust published evidence and are required for cancer staging, optimal patient management and prognosis. Core data items meet the requirements of professional standards (as defined by the Information Standards Board for Health and Social Care) and it is recommended that at least 95% of reports on cancer resections should record a full set of core data items. Other non-core data items are described. These may be included to provide a comprehensive report or to meet local clinical or research requirements. All data items should be clearly defined to allow the unambiguous recording of data.

The following stakeholders were contacted to consult on this document:

- Working Group of the British Association of Gynaecological Pathologists (BAGP), comprising BAGP Council and co-opted members
- British Gynaecologic Cancer Society (BGCS)
- International Collaboration on Cancer Reporting (ICCR).

The evidence has been evaluated according to the modified SIGN guidance and the level of evidence for the recommendations has been summarised according to College guidance (see Appendix H). No major conflicts in the evidence have been identified and any minor discrepancies between evidence have been resolved by expert consensus. This dataset was compiled based on an extensive literature review. The ICCR paper on recommendations for the dataset on ovary, fallopian tube and primary peritoneal carcinoma<sup>1</sup> was also consulted and items used from it following discussion with the Chair. The sections of this dataset that indicate compliance with each of the AGREE II standards are indicated in Appendix I.

No major organisational changes or cost implications have been identified that would hinder the implementation of the dataset.

A formal revision cycle for all cancer datasets takes place on a three-yearly basis. However, each year, the College will ask the author of the dataset, in conjunction with the relevant subspecialty adviser to the College, to consider whether or not the dataset needs to be updated or revised. A full consultation process will be undertaken if major revisions are required, i.e. revisions to core data items (the only exception being changes to international tumour grading and staging schemes that have been approved by the Specialty Advisory Committee on Cellular Pathology and affiliated professional bodies; these changes will be implemented without further consultation). If minor revisions or changes to non-core data items are required, an abridged consultation process will be undertaken whereby a short note of the proposed changes will be placed on the College website for two weeks for members' attention. If members do not object to the changes, the changes will be incorporated into the dataset and the full revised version (incorporating the changes) will replace the existing version on the College website.

The dataset has been reviewed by the Clinical Effectiveness department, Working Group on Cancer Services and Lay Governance Group and was placed on the College website for consultation with the membership from 16 January to 13 February 2019. All comments received from the Working Group and membership were addressed by the authors to the satisfaction of the Chair of the Working Group and the Clinical Lead for Guideline Review (Cellular Pathology).

This dataset was developed without external funding to the writing group. The College requires the authors of datasets to provide a list of potential conflicts of interest; these are monitored by the Clinical Effectiveness department and are available on request. The authors have declared no conflicts of interest.

## 1 Introduction

This document provides the dataset for the histopathological reporting of primary neoplasms of the ovaries, fallopian tubes and peritoneum in resection specimens and replaces the original versions of the dataset.

This new dataset has been extensively revised to align with the corresponding 2015 ICCR dataset.<sup>1</sup> It is hoped that regular application of these datasets will allow consistency of reporting of these tumours for accurate staging, treatment and inclusion criteria for clinical trials. This dataset has been compiled to reflect the recent extensive work that has increased understanding of ovarian epithelial cancer primary origin (i.e. arising from the fimbrial end of the fallopian tube from serous tubal intraepithelial carcinoma [STIC]) and the subsequent need for change in sampling protocols, in particular regarding risk-reducing bilateral salpingo-oophorectomies for patients with *BRCA* mutations.<sup>2</sup> In addition, it incorporates the revised 2014 FIGO staging system for ovarian, tubal and peritoneal carcinomas.<sup>3</sup> The scope of this dataset, therefore, is to focus on borderline and malignant epithelial tumours of the ovary, fallopian tube and peritoneum. Guidance for assignation of primary site of origin is provided in line with recent publications and the ICCR datasets. Finally, a proposal is presented for the scoring of the response to neoadjuvant chemotherapy. We hope that this will be adopted consistently around the UK to give a reproducible and comparable three-tier system for response assessment. Most gynaecological oncologists use the FIGO staging system for gynaecological cancers. However, TNM staging is included in this dataset to allow standardisation of staging across all cancer sites. Depending on local protocols, clinicians may elect to include TNM staging in gynaecological cancer datasets. The 8th edition of the TNM Classification of Malignant Tumours from the Union for International Cancer Control came into effect on 1 January 2018 and should be used for TNM staging.<sup>4</sup> It is also now recommended that the histological subtype of ovarian cancer be designated at staging.<sup>3</sup>

There is now greater clarity with regard to the recognition that ovarian carcinoma is not a single disease but comprises five major histological subtypes of which high-grade serous carcinoma is the most common, accounting for >75% of the ovarian carcinomas encountered.<sup>5</sup> These five major subtypes differ in their epidemiological risk factors, molecular genetics, morphology, immunophenotype, behaviour and response to treatment.<sup>6,7</sup>

Use of the dataset is advocated in the context of the multidisciplinary team meeting (MDTM) as an adjunct to clinical decision-making relevant to the treatment of each individual patient. The final staging should be allocated to each patient at the MDTM when all the available information is accessible.

This dataset should be completed for each borderline or malignant epithelial tumour of ovarian, tubal or peritoneal origin. The completion of the dataset will also facilitate regular audit and review of all aspects of the service and the collection of accurate data for cancer registries, providing feedback for those caring for patients with cancer. It is important to have robust local processes in place to ensure that the MDTM clinical leads and other key

members and cancer registries are informed of supplementary or revised histology reports that may affect patient treatment and data collection.

**Table 1: List of core and non-core data items.**

	<b>Core</b>	<b>Non-core</b>
<b>Request form</b>	<ul style="list-style-type: none"> <li>• Prior chemotherapy</li> <li>• Specimen type</li> <li>• Previous biopsy and/or cytology results</li> <li>• Capsule status</li> <li>• Tumour marker results (where performed/available)</li> </ul>	<ul style="list-style-type: none"> <li>• Genetic status</li> </ul>
<b>Macroscopy</b>	<ul style="list-style-type: none"> <li>• Capsule status</li> <li>• Tumour site</li> <li>• Dimensions of omentum</li> <li>• Omental involvement</li> <li>• Size of maximum omental deposit</li> </ul>	<ul style="list-style-type: none"> <li>• Tumour dimensions</li> <li>• Block key</li> </ul>
<b>Microscopy</b>	<ul style="list-style-type: none"> <li>• Tumour type</li> <li>• Grade</li> <li>• Sites of involvement</li> <li>• Peritoneal cytology</li> <li>• Lymph node status</li> <li>• Provisional stage (FIGO)</li> </ul> <p>For borderline serous tumours, additional core data items are:</p> <ul style="list-style-type: none"> <li>• micropapillary architecture</li> <li>• presence of implants</li> </ul>	<ul style="list-style-type: none"> <li>• Pattern of invasion (mucinous tumours)</li> <li>• Carcinosarcoma subtypes</li> <li>• Chemotherapy response score (CRS)</li> <li>• Coexistent pathology</li> <li>• Immunohistochemical and molecular ancillary data</li> </ul> <p>For borderline mucinous tumours, an additional non-core data item is:</p> <ul style="list-style-type: none"> <li>• intraepithelial carcinoma</li> </ul>

## 1.1 Target users and health benefits of these guidelines

The target primary users of the dataset are trainee and consultant cellular pathologists and, on their behalf, the suppliers of IT products to laboratories. Standardised cancer reporting and multidisciplinary team working reduce the risk of histological misdiagnosis and help to ensure that clinicians have all of the relevant pathological information required for tumour staging, management and prognosis. Collection of standardised cancer-specific data also provides information for healthcare providers and epidemiologists, and facilitates international benchmarking and research.

## 2 Specimen request form

### 2.1 Core data items

#### 2.1.1 Patient demographics

The request form should include full patient details including demographics. In addition to the hospital number, it is advised that the NHS number should also be included wherever possible, as this is a unique identifier across geographic sites. The name of the consultant allows future communication and ensures the report is sent to the correct clinician.

### **2.1.2 Time and date of operation**

This will be important for audit of the 62-day target and monitoring time between receipt and reporting of pathological samples. Time and date of specimen receipt is also useful in situations where delays occur between the site of operation and receipt in the laboratory, to aid accurate error logging and incident reporting.

*[Level of evidence – GPP.]*

### **2.1.3 Specimen type**

This allows correlation of pot labels with the form to avoid laboratory errors and is particularly important in cases with multiple specimens (which may arrive separately, such as when the fresh main specimen is received first for tissue collection) or when the normal anatomy is unclear from the macroscopic examination.

### **2.1.4 Previous biopsy and cytology results**

Knowledge of the result of any previous diagnostic specimens is key to the optimum specimen handling of any resections and also allows familiarity for frozen section purposes.

*[Level of evidence – GPP.]*

### **2.1.5 Tumour marker results**

Tumour marker results (when performed), for example CA125, CEA, CA19.9, alpha-fetoprotein and inhibin, should be included.

*[Level of evidence – GPP.]*

### **2.1.6 Prior (neoadjuvant) chemotherapy**

The morphological features (both at macroscopic and microscopic level) may be dramatically altered as a result of chemotherapy and therefore knowledge of the chemotherapy status of the patient is crucial. A biopsy performed prior to commencing treatment is the usual protocol for confirmation of diagnosis and referral to the pre-treatment sample may be necessary before assigning a final histotype to the resection specimens. A cell block made from a cytology sample, with appropriate immunohistochemical investigations, may be the only source of original chemotherapy-naive material in exceptional circumstances. Knowledge of prior chemotherapy will also allow the pathologist to take appropriate blocks at the time of specimen dissection for tumour regression grading (TRG/CRS – see section 6.2.4). TRG provides valuable prognostic information in patients who have been treated with neoadjuvant chemotherapy and may guide further treatment, including entry into trials.

*[Level of evidence – D.]*

### **2.1.7 Capsule status**

For ovarian neoplasms it is important to record any perioperative complications that might have resulted in loss of capsular integrity or any evidence of leakage of cyst contents during surgery. The cyst is sometimes submitted as fragments if it has been deflated when removed laparoscopically. The pathologist should be made aware of this. Approximately 25% of ovarian and primary tubal carcinomas present as stage I at diagnosis; those rupturing during surgery are assigned FIGO stage IC1, while those that have ruptured prior to surgery are considered FIGO stage IC2, according to the 2014 FIGO classification.<sup>3</sup> A recent meta-analysis<sup>8</sup> assessed risk factors for survival and demonstrated that progression-free survival was worse for patients with preoperative rupture. Conversely, patients with perioperative rupture did not have a significantly worse outcome than those with no rupture, when a complete surgical staging procedure had been carried out, with or without postoperative platinum-based chemotherapy.<sup>8</sup>

*[Level of evidence – B.]*

## 2.2 Non-core data items

### 2.2.1 Genetic status

The cause of 10–15% of carcinomas of the ovary and fallopian tube is thought to be either germline mutations in *BRCA1* or *BRCA2* (approximately 90%) or Lynch syndrome (LS; approximately 10%).<sup>9–11</sup> *BRCA* mutations are associated with high-grade serous carcinomas (up to 23% of patients)<sup>12</sup> while LS is associated with non-serous histotypes (principally endometrioid and clear cell carcinoma). It is understood that preoperative genetic status is often not available. Moreover, up to 45% of patients found to have a germline mutation may not have any family history of breast or ovarian carcinoma. However, genetic status remains a recommended data element for the following reasons:

- high-grade serous carcinomas associated with *BRCA* mutations are more likely to show a combination of particular morphological features, namely solid, pseudoendometrioid and/or transitional cell-like (SET) features, higher mitotic rates, prominent nuclear pleomorphism with bizarre forms, dense tumour-infiltrating lymphocytes and necrosis.<sup>13,14</sup> If the genetic status is known, pathologists may be better placed to correlate these features with a *BRCA* mutation, reducing the likelihood of misclassification as another histotype. However, it should be noted that this morphology is neither specific nor exclusive to *BRCA*-positive mutation cases. Implications of *BRCA* mutations include better prognosis, a higher rate of platinum sensitivity and the possibility of targeted chemotherapy regimens, including PARP inhibitors.<sup>12</sup> If patients are found to have a germline mutation, they and their relatives can be referred for genetic counselling and screening.
- knowledge of genetic status allows appropriately thorough sampling of resection specimens (please refer to section 5 of this dataset and the College's *Tissue pathways for gynaecological pathology*<sup>15</sup> for further guidance)
- approximately 2% of all ovarian cancers are associated with LS, which is caused by a germline mutation in one of the four genes encoding DNA mismatch repair (MMR) proteins. Women with LS have an increased lifetime risk (7–15%) of developing an ovarian cancer compared with the general population (1–2%); 60% of women with LS who develop cancer will have a gynaecological cancer (ovarian or endometrial) as their 'sentinel' cancer.<sup>10</sup> Mutations in *MSH2* appear to be most commonly associated with ovarian cancers.<sup>16</sup> MMR immunohistochemistry should be considered in cases of endometrioid or clear cell subtypes, or when personal or family history raises the possibility of LS. The presence of other non-*BRCA*/LS ovarian cancer syndromes is noted; however, these are rare and no genotype–phenotype correlations have yet been identified.<sup>17</sup>

[Level of evidence – B.]

## 3 Preparation of the specimen before dissection

Careful inking of the capsular surface can be helpful at possible sites of involvement or capsular defect, although it is not a universally adopted practice. The neoplasm may be sliced the previous day to allow adequate fixation. At this time it is worthwhile topping up the formalin in the container as the specimen often arrives in either inadequate amounts of formalin or in a container far too small for the size of the specimen. It is recommended that inking and slicing of the neoplasm only be undertaken following careful examination of the capsular surface of the ovary. The specimen should be examined for adhesions that may indicate foci of capsular rupture. Note that surgical rupture can sometimes occur and these slits within the capsule must be searched for as part of a thorough examination. Occasionally, the tube may form a mass when closely entangled with the ovary or the fimbrial end may be seen to merge with the ovarian capsule, therefore it may not be possible

to examine this end. The presence or evidence of previous sterilisation either by ligation or as a consequence of Filshie or Hulka clips should be noted.

Prior opening of the accompanying uterus is recommended to enable fixation of the endometrium, which is prone to autolytic changes if not exposed to formalin soon after receipt in the laboratory.

A photographic record of the specimen may be useful on an individual case basis when warranted, for example in cases of capsular breach or surface tumour, or ovarian masses with unusual macroscopic appearances.

## **4 Specimen handling and block selection: data items**

### **4.1 Core data items**

#### **4.1.1 Specimen type**

This allows confirmation that the specimen received is correct, and prompts identification of any structures mentioned on the request form. Laterality should also be given if applicable.

*[Level of evidence – GPP.]*

#### **4.1.2 Capsule status**

As described in section 2.1.7, this is important for staging purposes.

#### **4.1.3 Macroscopic tumour site**

Assigning site of origin is essential for high-grade serous carcinomas. Please see section 6.1.5 for guidance on designation of the likely site of origin by histological assessment.

*[Level of evidence – B.]*

#### **4.1.4 Macroscopic description of omentum**

The description should include:

- dimensions
- involvement
- maximum dimension of the largest deposit.

An infracolic omentectomy is usually performed as part of the staging procedure for a suspected ovarian carcinoma. Occasionally, only an omental biopsy will be performed. The omentum should be measured in three dimensions. The presence or absence of gross tumour involvement should be documented and the size of the largest tumour nodule measured. The latter is important in the substaging of stage III ovarian carcinomas. The size of the specimen is also helpful to guide extent of sampling; however, if the omentum is grossly involved, a single block of tumour with macroscopic description of the greatest dimension of tumour deposit is sufficient for accurate staging.<sup>18,19</sup> No guidelines exist for adequate sampling of grossly uninvolved omental specimens; however, sampling in five blocks has been demonstrated to give good sensitivity.<sup>20</sup> Therefore, we advise sampling in four to six blocks, in line with the ICCR recommendations, depending on the size of omentum received.<sup>1</sup> Note, in the presence of serous borderline tumours with exophytic components, implants are neither visible nor palpable and to exclude their presence sampling of eight to ten blocks may be more appropriate.

*[Level of evidence – GPP.]*



## 4.2 Non-core data items

### 4.2.1 Tumour dimensions

Historically, the tumour has been described in three dimensions. This is helpful in visualising tumour volume (particularly if the sections are sent for a second opinion) and allowing appropriate sampling.

*[Level of evidence – D.]*

### 4.2.2 Block identification key

Accurate description of the origin for all tissue blocks is important, in particular if the case is required for external or internal review, or block retrieval for further molecular or immunohistochemical testing is required (e.g. as part of a trial or to ascertain drug susceptibility). To this end, a note of an appropriate tumour block at the end of the block key is to be encouraged as this will allow rapid retrieval without requiring re-review of sections.

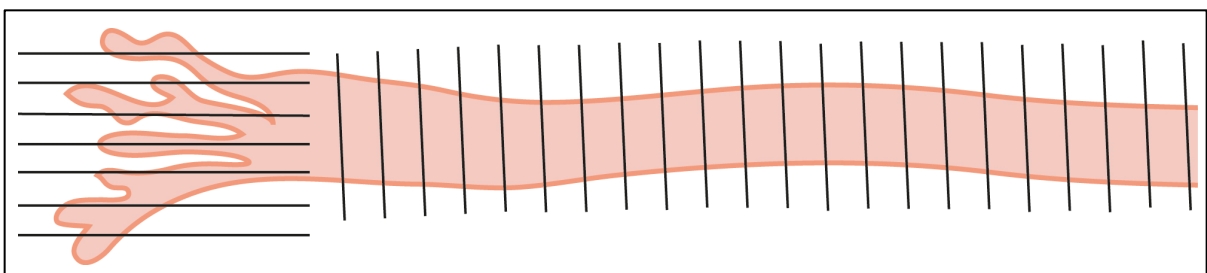
*[Level of evidence – C.]*

## 5 Specimen handling and block selection: a guide

### 5.1 Ovarian masses

It is recommended that all ovarian masses are measured in three dimensions. Specimen weight may be recorded if desired. The presence and appearance of the fallopian tube should be recorded, and a note made of whether the fimbrial end is visible or inseparably incorporated into a tubo-ovarian mass. This is important in designation of the site of origin in high-grade serous carcinomas, and determines if the fimbrial end can be sampled as per the SEE-FIM (sectioning and extensive examination of the fimbria) protocol (see Figure 1).

**Figure 1: The SEE-FIM protocol.** The fimbrial end is sectioned parallel to the long axis of the tube, with the remainder of the tube transversely sectioned at 2 mm intervals, and entirely embedded. This is recommended for risk-reducing macroscopically normal salpingo-oophorectomies and may be modified for ovarian carcinoma specimens.



It is important to determine whether the ovarian capsule is intact. If rupture is identified, discussion at the MDTM or reference to the operation notes may be helpful in concluding whether this occurred at or prior to surgery. Inking of the capsular surface may help guide later microscopic assessment of capsular breach.

The specimen may be received fresh for frozen section diagnosis, at which point the ovarian tumour should be examined and suspicious (solid, papillary) areas should be sought and preferentially selected for frozen section examination. The limitations of frozen section diagnosis (in particular for borderline tumours and in overdiagnosis of clear cell carcinoma) have been discussed elsewhere.<sup>21,22</sup> The ovarian mass should be sliced and its cystic or solid nature noted, as well as the presence and size of papillary excrescences.

Adequate sampling is paramount. The recommendation extrapolated from gross dissection of soft tissue tumours (to submit entirely any tumour <2 cm and to submit a minimum of one block per 10 mm for tumours >2 cm) has been generally adopted. Ovarian tumours are often heterogeneous, and adequate sampling is important for numerous reasons including: in borderline tumours to exclude microinvasive foci; to identify small foci of carcinosarcoma in high-grade serous carcinoma; to identify histologically diagnostic areas in poorly differentiated neoplasms or those with heterologous elements or displaying multiple lines of differentiation. Mucinous carcinomas are the most heterogeneous group of tumours<sup>22</sup> with very focal stromal invasion often occurring. Therefore, consideration of more extensive sampling in mucinous tumours with borderline morphology or intraepithelial carcinoma is mandated. In addition, it is recommended that two blocks per 10 mm should be taken in borderline tumours >10 cm in size, or in cases where the diagnosis has been made at frozen section or prior to sampling of the main specimen.<sup>23,24</sup> However, with a large homogenous neoplasm or a simple, thin-walled cystic lesion without capsular thickening or papillary processes, more limited sampling may be appropriate with the option of further sampling should this be indicated.

Sampling should be centred on any papillary and solid areas, in addition to thin-walled cystic components. The former are typically the foci of stromal invasion or malignancy, while cystic components are useful to demonstrate pre-existent or background changes such as endometriosis. Ovarian cysts that are entirely thin walled may be rolled up analogous to a 'membrane roll' in placentas, to enable a higher surface area to be represented in a single block.

## **5.2 Fallopian tube**

As it is now recognised that most high-grade serous carcinomas arise from the fimbrial end of the fallopian tube, a SEE-FIM-like protocol should be undertaken on all macroscopically normal tubal resections for ovarian carcinomas (other than high-grade serous carcinoma) and borderline tumours. Such a protocol comprises slicing the fimbria parallel to the long axis and submitting it entirely together with representative transverse sections of the non-fimbrial end. Submission of the entire tube using a SEE-FIM protocol (see Figure 1), however, is advocated in cases of high-grade serous carcinoma with bilateral macroscopically normal tubes. Although the number of premalignant or malignant lesions identified is small (reported in 0.7% of patients), it would be reasonable to suggest adopting the above SEE-FIM-like protocol (which includes submission of the entire fimbrial end without necessarily embedding the entire tube) for all other tubal resections, including resections undertaken for benign conditions. In patients with a high risk of familial tubo-ovarian malignancy, the full SEE-FIM protocol is required. Employment of this protocol will facilitate early identification of occult STIC and invasive high-grade serous carcinoma, and the additional effort and number of blocks required is small.

## **5.3 Appendix**

This should be inspected and described, including any serosal nodules or luminal dilatation, and the contents noted, in particular the presence of mucinous material. The entire appendix should be embedded when the ovarian mass is mucinous in nature, as the primary appendiceal neoplasm in cases of occult metastatic disease may be microscopic.

## **5.4 Lymph node biopsies**

Lymph nodes should be submitted in separate pots that are labelled according to their site of origin. The number of lymph nodes retrieved from each site should be recorded. The presence of macroscopic involvement of lymph nodes by the tumour should be recorded. All retrieved lymph nodes must be examined histologically in their entirety. However, representative sections are all that are required for those lymph nodes that are obviously involved by the tumour to confirm the presence of metastatic disease, bearing in mind that

the presence of extracapsular spread may become prognostically important in the future, while the remainder should be sliced along the short axis (i.e. sliced perpendicular to the long axis) at 2–3 mm intervals and submitted in their entirety for histological examination. Nodes <5 mm can be bisected or processed whole. Consideration may be given to multiple lymph nodes <3 mm being submitted whole in one cassette as they would be too small to slice. This should be detailed on the macroscopic report within the block key.

## 5.5 Peritoneal biopsies

These should be submitted in separate pots and labelled as to their site of origin. They should be submitted in their entirety for histological examination if macroscopically normal, but a single section may suffice if they are obviously involved by the tumour; this is left to the individual pathologist's discretion.

## 6 Microscopic description

### 6.1 Core data items

#### 6.1.1 Histological type (carcinomas and borderline tumours)

Histological tumour subtype should be allocated for both borderline tumours and carcinomas of the ovary as defined by the WHO classification (Appendix A).<sup>25</sup> Carcinosarcoma is classified as a mixed epithelial and mesenchymal malignancy, but is included in this classification as most are now understood to derive from an epithelial origin.<sup>26</sup> The most common subtype is high-grade serous carcinoma, followed by endometrioid and clear cell carcinoma.<sup>27,28</sup>

Management of ovarian carcinoma is currently largely still dependent on tumour stage. However, introduction of targeted therapies has already begun (e.g. PARP inhibitors in *BRCA*-associated high-grade serous carcinoma) and, as discussed in section 2.2.1, diagnosis of discrete tumour types may indicate an underlying germline mutation.<sup>9–12</sup> There is also an increasing understanding that these defined subtypes of ovarian carcinoma are associated with different molecular pathogenesis and therefore have distinct natural histories and responses to chemotherapy.<sup>28–32</sup> Please refer to Appendix C for immunohistochemical aids in diagnosis.

Mixed carcinomas have been omitted in the most recent WHO classification.<sup>25</sup> They are now diagnosed less often as it is now established through molecular studies that those previously diagnosed as mixed high-grade serous and clear cell/endometrioid represent high-grade serous carcinoma demonstrating a range of morphologies. However, mixed carcinomas do still occur (in the region of 1% of all epithelial ovarian carcinomas),<sup>33</sup> often in the setting of endometriosis with mixed clear cell and endometrioid carcinomas, and the proportion of each subtype should be detailed in the report (even if they comprise <10% of total tumour by volume).

Seromucinous carcinomas are described in the most recent WHO classification<sup>25</sup> but their status as a discrete entity has recently been disputed.<sup>34</sup> It is therefore recommended that these tumours be recognised as representing either endometrioid carcinoma or low-grade serous carcinoma, and classified as such following thorough sampling and adjunctive immunohistochemical investigations as required (please refer to Appendix C).

*[Level of evidence – A.]*

#### 6.1.2 Tumour grade

Despite the presence of various universal grading systems, it is recommended that different tumour grading methods should be utilised based on the histological subtype. Grading

should be performed on the initial diagnostic biopsy as post-chemotherapy biopsies are unreliable owing to morphological alterations.

### **Serous carcinoma**

It is now well established that low- and high-grade serous carcinoma represent two distinct tumour entities characterised by different underlying molecular pathways and response to treatment.<sup>35</sup> Therefore, grade should be assigned using a binary two-tier system.<sup>36,37</sup> It is recognised that in exceedingly rare cases, both high- and low-grade serous carcinoma may co-exist, or the former may have originated from the low-grade element.<sup>38,39</sup>

Low-grade serous carcinoma should demonstrate only mild nuclear atypia with a mitotic index of <12 mitoses/10 high power field and be devoid of necrosis. Conversely, high-grade serous carcinoma demonstrates widespread nuclear pleomorphism (in excess of a nuclear size ratio of 3:1), a high mitotic rate and in 95% of cases is associated with an aberrant p53 immunophenotype (diffuse strong positivity, and null or rare granular cytoplasmic staining patterns).<sup>40</sup>

### **Clear cell carcinoma, undifferentiated carcinoma and carcinosarcoma**

These are by definition high-grade tumours.

### **Endometrioid carcinoma**

It is recommended that carcinomas of endometrioid type are classified according to the FIGO grading system, analogous to those arising within the endometrium. The 1988 FIGO grading system is based on architecture as follows: grade 1 = <5% solid component; grade 2 = 5–50% solid component; grade 3 = >50% solid component (with squamous metaplasia not included in the architectural assessment). When low-grade (1–2) tumours show marked cytological atypia, the grade should be increased by one; however, this is often a clue to a high-grade serous carcinoma with glandular growth pattern and this should be excluded by use of immunohistochemistry.

Effort should be made to reclassify those tumours that would previously have been diagnosed as seromucinous carcinomas as either endometrioid or low-grade serous carcinomas (please see section 6.1.1)<sup>34</sup> and graded as such.

### **Mucinous carcinoma**

There is no separate evidence-based grading system for primary ovarian mucinous carcinomas. It is recommended that they be graded in a similar manner to endometrioid carcinomas. The presence of a malignant sarcomatoid mural nodule renders any mucinous carcinoma high grade (grade 3).

### **Borderline tumours**

The cut-off between the diagnoses of benign cystadenoma/cystadenofibroma with focal proliferation and ovarian borderline tumour is subject to much interobserver variation.<sup>41</sup> Some studies have suggested a threshold of 10% of the tumour showing these changes and this is the recommendation for all epithelial subtypes. However, this remains an arbitrary cut-off, may give rise to interobserver variability and is dependent on many factors including sampling techniques. In cases such as extensive torsion-related infarction, a lower threshold may be prudent and diagnosis is left at the discretion of the individual pathologist.

*[Level of evidence – B.]*

#### **6.1.3 Implants (serous borderline tumours)**

The presence of epithelial implants in various intra-abdominal sites is relatively common (approximately 20%) in the presence of an ovarian serous borderline tumour.

Following the WHO 2014 publication, invasive implants are now classified as low-grade serous carcinoma,<sup>25</sup> therefore differentiation between invasive and non-invasive implants is

of utmost importance for management and prognosis.<sup>42</sup> Non-invasive implants show no stromal infiltration and often appear 'stuck on' the peritoneal surface. It is recognised that this can be a difficult and subjective area.<sup>43,44</sup>

In the small number of cases in which it is not possible to determine whether an implant is invasive or non-invasive, the term 'indeterminate type' may be used.<sup>25</sup> However, obtaining an expert second opinion, submitting further blocks or performing further levels should be considered as first-line options to resolve this question. This category should only be used in very rare circumstances.

Other borderline tumour types (mucinous, endometrioid, etc.) do not give rise to implants and therefore if an implant is identified this represents metastasis. In these cases, further blocks should be taken from the primary ovarian tumour and radiological review undertaken to exclude an unsampled primary carcinoma or occult metastatic non-ovarian malignancy.

*[Level of evidence – B.]*

#### **6.1.4 Special features in borderline tumours**

##### **Microinvasion**

Microinvasion usually occurs within serous or mucinous borderline tumours and in most studies has not been found to affect prognosis. Investigators have set different thresholds for the upper limit of diagnosis of microinvasion (ranging from 1 to 5 mm) and some use area rather than maximum diameter.<sup>25,41,43,45</sup> We endorse the WHO suggestion of 5 mm. Stromal invasion may be encountered as individually infiltrating cells (usually seen in association with serous borderline tumours), destructive stromal invasion or expansile invasion (back-to-back glands, usually mucinous borderline tumours). Microinvasion may be multifocal and, if spatially discrete, these foci should be regarded as separate areas and not added together.

##### **Micropapillary architecture**

Many serous borderline tumours have small foci of micropapillary architecture (defined as non-hierarchical branching with papillae of height >5 times the width).<sup>25</sup> A micropapillary borderline tumour should have at least one confluent area displaying micropapillary architecture with a dimension of at least 5 mm.

*[Level of evidence – C.]*

#### **6.1.5 STIC and allocation of primary site of origin in high-grade serous carcinoma**

As described in section 5.2, it is now recognised that the majority of high-grade serous carcinomas arise in the fimbrial end of the fallopian tube. When processed with the SEE-FIM technique, intraepithelial lesions and small intramucosal carcinomas are frequently identified. When combined with p53 and Ki67 immunohistochemistry, diagnosis of STIC is highly reproducible (mutant p53 immunophenotype and Ki67 labelling of >10% in the setting of pleomorphic cells with loss of cilia).<sup>46,47</sup> Precursor lesions not amounting to STIC (tubal intraepithelial lesion in transition/serous tubal intraepithelial lesion) are well established, but their clinical significance remains unclear.<sup>48</sup>

One caveat in high-grade serous carcinoma is that uterine serous carcinomas may secondarily involve the fallopian tube and mimic a primary STIC lesion.<sup>49</sup> Equally, other non-gynaecological primary malignancies may behave in a similar manner.<sup>50</sup> Immunohistochemistry for PAX8, WT1 and p53 may be useful for differentiation (see Appendix C).

It is anticipated that with careful sampling of the fallopian tube, the majority of high-grade serous carcinomas will be found to be of tubal origin. Failure to detect the fallopian tube either macroscopically or microscopically implies overgrowth by a tumour and is still suggestive of a tubal primary. Assignment of an ovarian or peritoneal primary site is therefore only achieved by excluding any tubal mucosal involvement (and ovarian parenchymal

involvement in the case of a primary peritoneal tumour; see Table 2).<sup>51</sup> It should be noted that in interval debulking specimens post-chemotherapy (in which there may have been significant tumour regression), if clear evidence of tubal or ovarian origin is not found, tumours should be classified as tubo-ovarian in origin. A designation of primary peritoneal carcinoma can only be made when tubal and ovarian disease has been excluded by complete pathological examination prior to chemotherapy, i.e. in primary debulking surgical specimens.<sup>51</sup> Cases in which both endometrial and tubal/ovarian involvement is found should be assessed carefully – with immunohistochemical evaluation – to determine the likely primary site of origin.

[Level of evidence – A.]

**Table 2: Assignment of primary site of origin.**

Primary site	Criteria
Fallopian tube	<ol style="list-style-type: none"> <li>1. STIC present</li> <li>2. Invasive mucosal carcinoma present within the fallopian tube, regardless of the presence of STIC, or ovarian or peritoneal disease.</li> <li>3. Fallopian tube partly or wholly incorporated into a tubo-ovarian mass, regardless of the presence of STIC, or ovarian or peritoneal disease.</li> </ol>
Ovary	An ovarian mass or microscopic involvement of the ovary by high-grade serous carcinoma is present, <b>in the absence</b> of STIC or mucosal tubal carcinoma (when examined by a SEE-FIM protocol, see Figure 1).
Tubo-ovarian	<ol style="list-style-type: none"> <li>1. Small biopsy specimen including cytology samples. This should be supported by appropriate immunohistochemistry to exclude the possibility of a uterine serous primary.</li> <li>2. Post-chemotherapy with no residual disease.</li> </ol>
Primary peritoneal	This should <b>only</b> be assigned in primary debulking specimens (i.e. prior to chemotherapy). Peritoneal high-grade serous carcinoma is present <b>in the absence</b> of macroscopic or microscopic involvement of the ovaries (including surface involvement) or tubal mucosa. It is confirmed by appropriate immunohistochemistry to exclude mesothelioma and metastatic carcinoma.

Note: Each individual criterion is sufficient for assignment of the primary site.

### 6.1.6 Histological sites of tumour involvement

This is necessary for adequate staging (which should be performed according to the FIGO staging system, see Appendix B). Tumours of the ovary, fallopian tube and peritoneum are all staged in the same manner.

[Level of evidence – B.]

### 6.1.7 Peritoneal cytology

Peritoneal cytology status is required for accurate staging of stage I ovarian tumours (positive cytology upstages to FIGO stage IC3) and may influence the decision for adjuvant treatment.

[Level of evidence – B.]

### 6.1.8 Lymph node status

It is important to report the site of involved lymph nodes since any extraperitoneal lymph node involvement (including inguinal lymph nodes) represents stage IV disease. Measurement of the size of the metastatic deposit is also necessary, as the revised 2014 FIGO staging system classifies retroperitoneal (pelvic, para-aortic) nodal metastases measuring up to 10 mm as IIIA1(i) and those >10 mm as IIIA1(ii). It has been suggested that in rare cases of intra-abdominal lymph node metastases without retroperitoneal involvement, these should be staged as FIGO IIIC, and they are regarded as intra-abdominal disease.<sup>1</sup>

Lymph node involvement in the setting of serous borderline tumours is common (around 25%) and does not appear to affect overall survival.<sup>52,53</sup> The exception to this is confluent nodular aggregates measuring >1 mm,<sup>40</sup> which may be associated with a poorer survival and invasive foci in the omentum. Similarly, the involvement of nodal sinuses by non-invasive small epithelial groups representing serous borderline tumour should be distinguished from invasive nodal implants with desmoplasia, representing low-grade serous carcinoma.

*[Level of evidence – B.]*

### 6.1.9 Provisional pathological staging pre-MDTM

It is strongly recommended that the final FIGO stage should be assigned at the gynaecology MDTM when all the patient-related information is available. TNM staging is optional.

*[Level of evidence – D.]*

## 6.2 Non-core data items

### 6.2.1 Pattern of invasion (mucinous carcinomas)

Mucinous carcinomas may show an expansile pattern of invasion or destructive stromal invasion. Expansile invasion is characterised by back-to-back glands that may be architecturally complex and are lined by atypical epithelium, analogous to the diagnosis of invasion in endometrioid carcinomas. Destructive stromal invasion is identified by glands, nests, cords or single cells invading stroma with an associated oedematous, desmoplastic or inflammatory response. It should be noted that in cases with extensive destructive stromal invasion, metastatic carcinoma should be considered. There is controversy around whether or not these patterns confer any survival advantage.<sup>54,55</sup>

*[Level of evidence – B.]*

### 6.2.2 Carcinosarcoma subtypes

It may be helpful to provide the clinician with both the epithelial (usually high-grade serous carcinoma) and mesenchymal subtypes, in particular the presence of heterologous sarcomatous elements. The availability of this information will be useful in cases of recurrences. It might also be helpful to provide the clinician with the ratio of epithelial to stromal components. No prognostic difference has been demonstrated between the presence of heterologous and homologous elements, although any prognostic difference for the presence of specifically rhabdomyosarcomatous differentiation has not been studied.<sup>56,57</sup>

*[Level of evidence – GPP.]*

### 6.2.3 Presence of intraepithelial carcinoma (mucinous borderline tumours)

This is another controversial area that may have large interobserver variation.

*[Level of evidence – C.]*

### 6.2.4 Response to neoadjuvant chemotherapy

Many cases of advanced stage ovarian carcinoma are now treated with neo-adjuvant chemotherapy, and subsequently patients undergo interval debulking surgery at the third or fourth cycle. The CRS has been validated for use in high-grade serous carcinoma and shows good reproducibility.<sup>58-61</sup> It also correlates with progression-free survival and is therefore important as a prognostic tool and to guide future therapy in cases where there is histological evidence of poor response.<sup>58,60,61</sup>

**Table 3: Chemotherapy response score.**

Score	Criteria	Tumour regression grading
1	Mainly viable tumour with minimal regression-associated fibro-inflammatory changes limited to a few foci*	No or minimal tumour response
2	Multifocal or diffuse regression-associated fibro-inflammatory changes, with viable tumour ranging from diffuse sheets, streaks or nodules to extensive regression with multifocal but easily identifiable residual tumour	Partial tumour response
3	Mainly regression, with few irregularly scattered individual tumour cells or cell groups (all measuring <2 mm), or no residual tumour identified	Near-complete or complete response

\*Where fibro-inflammatory changes are denoted by fibrosis associated with macrophages including foam cells, mixed inflammation cells and Psammoma bodies; to be distinguished from tumour-related inflammation or desmoplasia. Adapted from McCluggage *et al.*<sup>1</sup> and Böhm *et al.*<sup>58</sup>

As set out by the ICCR,<sup>1</sup> the scoring method to be followed is detailed here:

- scoring should be carried out on a single haematoxylin and eosin-stained section of omentum
- the block selected should be the block in which **the least** response to chemotherapy is seen
- the amount of viable tumour should be assessed and CRS assigned as per the criteria in Table 3
- in cases where no evidence of tumour is seen (i.e. no fibro-inflammatory changes including Psammomatous calcification) or no residual carcinoma cells are identified, imaging reports should be checked to identify whether the tumour was present in the omentum prior to chemotherapy. If no omental involvement was reported, the CRS should not be given.

[Level of evidence – A.]

## 7 Diagnostic coding and staging

As described in section 5.1.9, provisional staging prior to the MDTM may be given. The FIGO stage should be given and coding performed using SNOMED CT codes (see Appendix A). It is noted, however, that SNOMED is now in a practical transition phase, as part of the intended full implementation by the NHS and Public Health England (PHE) of SNOMED CT. SNOMED ceased to be licensed by the International Health Terminology Standards Development Organisation from 26 April 2017. A list of applicable M SNOMED and SNOMED CT codes is provided in Appendix A. Mapping SNOMED CT terminology is provided. The UICC TNM stage (the 8th edition is in use as of 1 January 2018) remains optional.



## 8 Reporting of small biopsy specimens

In cases where a total primary surgical cytoreduction is feasible, most carcinomas of ovarian/tubal/primary peritoneal origin are now removed following extensive radiological and clinical investigation, without a prior histopathological diagnosis.

However, the use of radiologically guided core biopsies via the omental or transvaginal route for diagnosis prior to treatment with neoadjuvant chemotherapy has become more frequent and is now routine practice in patients with widespread or bulky disease. They are also performed in patients who have had a previous carcinoma (particularly breast), or in which the pattern of disease is atypical, to confirm a gynaecological origin.

The number of core biopsies should be recorded and the length of each core documented. Preservation of tissue for further immunohistochemical and molecular testing is becoming increasingly important and therefore each core may be placed in separate cassettes to enable optimum utilisation.

## 9 Criteria for audit

As recommended by the RCPATH as key performance indicators (see *Key performance indicators – proposals for implementation*, July 2013, [www.rcpath.org/profession/quality-improvement/kpis-for-laboratory-services.html](http://www.rcpath.org/profession/quality-improvement/kpis-for-laboratory-services.html)):

- cancer resections must be reported using a template or proforma, including items listed in the English Cancer Outcomes and Services Dataset (COSD), which are by definition core data items in RCPATH cancer datasets. English Trusts were required to implement the structured recording of core pathology data in the COSD by January 2016 and to update their systems in line with subsequent COSD updates.
  - standard: 95% of reports must contain structured data
- histopathology cases must be reported, confirmed and authorised within seven and ten calendar days of the procedure
  - standard: 80% of cases must be reported within seven calendar days and 90% within ten calendar days.

## 10 References

1. McCluggage WG, Judge MJ, Clarke BA, Davidson B, Gilks CB, Hollema H *et al*. Data set for reporting of ovary, fallopian tube and primary peritoneal carcinoma: recommendations from the International Collaboration on Cancer Reporting (ICCR). *Mod Pathol* 2015;28:1101–1122.
2. Medeiros F, Muto MG, Lee Y, Elvin JA, Callahan MJ, Feltmate C *et al*. The tubal fimbria is a preferred site for early adenocarcinoma in women with familial ovarian cancer syndrome. *Am J Surg Pathol* 2006;30:230–236.
3. Prat J; FIGO Committee on Gynecologic Oncology. Staging classification for cancer of the ovary, fallopian tube, and peritoneum. *Int J Gynaecol Obstet* 2014;124:1–5.
4. Brierley JD, Gospodarowicz MK, Wittekind C (eds). *TNM Classification of Malignant Tumours* (8th edition). Oxford, UK: Wiley-Blackwell, 2017.
5. McCluggage WG. Morphological subtypes of ovarian carcinoma: a review with emphasis on new developments and pathogenesis. *Pathology* 2011;43:420–432.
6. Gurung A, Hung T, Morin J, Gilks CB. Molecular abnormalities in ovarian carcinoma: clinical, morphological and therapeutic correlates. *Histopathology* 2013;62:59–70.
7. Kobel M, Kalloger SE, Lee S, Duggan MA, Kelemen LE, Prentice L *et al*. Biomarker-based ovarian carcinoma typing: a histologic investigation in the ovarian tumor tissue analysis consortium. *Cancer Epidemiol Biomarkers Prev* 2013;22:1677–1686.
8. Kim HS, Ahn JH, Chung HH, Kim JW, Park NH, Song YS *et al*. Impact of intraoperative rupture of the ovarian capsule on prognosis in patients with early-stage epithelial ovarian cancer: a meta-analysis. *Eur J Surg Oncol* 2013;39:279–289.
9. Folkins AK, Longacre TA. Hereditary gynaecological malignancies: advances in screening and treatment. *Histopathology* 2013;62:2–30.
10. Chui MH, Gilks CB, Cooper K, Clarke BA. Identifying Lynch syndrome in patients with ovarian carcinoma: the significance of tumor subtype. *Adv Anat Pathol* 2013;20:378–386.
11. Prat J, Ribe A, Gallardo A. Hereditary ovarian cancer. *Hum Pathol* 2005;36:861–870.
12. Alsop K, Fereday S, Meldrum C, deFazio A, Emmanuel C, George J *et al*. BRCA mutation frequency and patterns of treatment response in BRCA mutation-positive women with ovarian cancer: a report from the Australian Ovarian Cancer Study Group. *J Clin Oncol* 2012;30:2654–2663.
13. Soslow RA, Han G, Park KJ, Garg K, Olvera N, Spriggs DR *et al*. Morphologic patterns associated with BRCA1 and BRCA2 genotype in ovarian carcinoma. *Mod Pathol* 2012;25:625–636.
14. Fujiwara M, McGuire VA, Felberg A, Sieh W, Whittemore AS, Longacre TA. Prediction of BRCA1 germline mutation status in women with ovarian cancer using morphology-based criteria: identification of a BRCA1 ovarian cancer phenotype. *Am J Surg Pathol* 2012;36:1170–1177.
15. Hirschowitz L, Faruqi A, Fulmali R, Ganesan R, McCluggage WG. *Tissue pathways for gynaecological pathology* (2nd edition). London, UK: The Royal College of Pathologists, 2015. Available at: [www.rcpath.org/profession/guidelines/cancer-datasets-and-tissue-pathways.html](http://www.rcpath.org/profession/guidelines/cancer-datasets-and-tissue-pathways.html)

16. Ryan NAJ, Morris J, Green K, Lalloo F, Woodward ER, Hill J *et al.* Association of Mismatch Repair Mutation With Age at Cancer Onset in Lynch Syndrome: Implications for Stratified Surveillance Strategies. *JAMA Oncol* 2017;3:1702–1706.
17. Schoolmeester JK, Moyer AM, Goodenberger ML, Keeney GL, Carter JM, Bakkum-Gamez JN. Pathologic findings in breast, fallopian tube, and ovary specimens in non-BRCA hereditary breast and/or ovarian cancer syndromes: a study of 18 patients with deleterious germline mutations in RAD51C, BARD1, BRIP1, PALB2, MUTYH, or CHEK2. *Hum Pathol* 2017;70:14–26.
18. Doig T, Monaghan H. Sampling the omentum in ovarian neoplasia: when one block is enough. *Int J Gynecol Cancer* 2006;16:36–40.
19. Usubutun A, Ozseker HS, Himmetoglu C, Balci S, Ayhan A. Omentectomy for gynecologic cancer: how much sampling is adequate for microscopic examination? *Arch Pathol Lab Med* 2007;131:1578–1581.
20. Skala SL, Hagemann IS. Optimal sampling of grossly normal omentum in staging of gynecologic malignancies. *Int J Gynecol Pathol* 2015;34:281–287.
21. Ratnavelu ND, Brown AP, Mallett S, Scholten RJ, Patel A, Founta C *et al.* Intraoperative frozen section analysis for the diagnosis of early stage ovarian cancer in suspicious pelvic masses. *Cochrane Database Syst Rev* 2016;3:CD010360.
22. Hoang LN, Zachara S, Soma A, Kobel M, Lee CH, McAlpine JN *et al.* Diagnosis of Ovarian Carcinoma Histotype Based on Limited Sampling: A Prospective Study Comparing Cytology, Frozen Section, and Core Biopsies to Full Pathologic Examination. *Int J Gynecol Pathol* 2015;34:517–527.
23. Gramlich T, Austin RM, Lutz M. Histologic sampling requirements in ovarian carcinoma: a review of 51 tumors. *Gynecol Oncol* 1990;38:249–256.
24. Silverberg SG, Bell DA, Kurman RJ, Seidman JD, Prat J, Ronnett BM *et al.* Borderline ovarian tumors: key points and workshop summary. *Hum Pathol* 2004;35:910–917.
25. Kurman RJ, Carcangiu ML, Herrington CS, Young RH. *WHO Classification of Tumours of Female Reproductive Organs* (4th edition). Lyon, France: IARC, 2014.
26. Ardighieri L, Mori L, Conzadori S, Bugatti M, Falchetti M, Donzelli CM *et al.* Identical TP53 mutations in pelvic carcinosarcomas and associated serous tubal intraepithelial carcinomas provide evidence of their clonal relationship. *Virchows Arch* 2016;469:61–69.
27. Seidman JD, Horkayne-Szakaly I, Haiba M, Boice CR, Kurman RJ, Ronnett BM. The histologic type and stage distribution of ovarian carcinomas of surface epithelial origin. *Int J Gynecol Pathol* 2004;23:41–44.
28. Gilks CB. Molecular abnormalities in ovarian cancer subtypes other than high-grade serous carcinoma. *J Oncol* 2010;2010:740968.
29. McCluggage WG. My approach to and thoughts on the typing of ovarian carcinomas. *J Clin Pathol* 2008;61:152–163.
30. Shih IeM, Kurman RJ. Ovarian tumorigenesis: a proposed model based on morphological and molecular genetic analysis. *Am J Pathol* 2004;164:1511–1518.
31. Gilks CB. Subclassification of ovarian surface epithelial tumors based on correlation of histologic and molecular pathologic data. *Int J Gynecol Pathol* 2004;23:200–205.

32. Soslow RA. Histologic subtypes of ovarian carcinoma: an overview. *Int J Gynecol Pathol* 2008;27:161–174.
33. Mackenzie R, Talhouk A, Eshragh S, Lau S, Cheung D, Chow C *et al.* Morphologic and Molecular Characteristics of Mixed Epithelial Ovarian Cancers. *Am J Surg Pathol* 2015;39:1548–1557.
34. Rambau PF, McIntyre JB, Taylor J, Lee S, Ogilvie T, Sienko A *et al.* Morphologic Reproducibility, Genotyping, and Immunohistochemical Profiling Do Not Support a Category of Seromucinous Carcinoma of the Ovary. *Am J Surg Pathol* 2017;41:685–695.
35. Singer G, Stohr R, Cope L, Dehari R, Hartmann A, Cao DF *et al.* Patterns of p53 mutations separate ovarian serous borderline tumors and low- and high-grade carcinomas and provide support for a new model of ovarian carcinogenesis: a mutational analysis with immunohistochemical correlation. *Am J Surg Pathol* 2005;29:218–224.
36. Malpica A, Deavers MT, Lu K, Bodurka DC, Atkinson EN, Gershenson DM *et al.* Grading ovarian serous carcinoma using a two-tier system. *Am J Surg Pathol* 2004;28:496–504.
37. Seidman JD, Horkayne-Szakaly I, Cosin JA, Ryu HS, Haiba M, Boice CR *et al.* Testing of two binary grading systems for FIGO stage III serous carcinoma of the ovary and peritoneum. *Gynecol Oncol* 2006;103:703–708.
38. Dehari R, Kurman RJ, Logani S, Shih le M. The development of high-grade serous carcinoma from atypical proliferative (borderline) serous tumors and low-grade micropapillary serous carcinoma: a morphologic and molecular genetic analysis. *Am J Surg Pathol* 2007;31:1007–1012.
39. Quddus MR, Rashid LB, Hansen K, Sung CJ, Lawrence WD. High-grade serous carcinoma arising in a low-grade serous carcinoma and micropapillary serous borderline tumour of the ovary in a 23-year-old woman. *Histopathology* 2009;54:771–773.
40. Casey L, Kobel M, Ganesan R, Tam S, Prasad R, Bohm S *et al.* A comparison of p53 and WT1 immunohistochemical expression patterns in tubo-ovarian high-grade serous carcinoma before and after neoadjuvant chemotherapy. *Histopathology* 2017;71:736–742.
41. Seidman JD, Soslow RA, Vang R, Berman JJ, Stoler MH, Sherman ME *et al.* Borderline ovarian tumors: diverse contemporary viewpoints on terminology and diagnostic criteria with illustrative images. *Hum Pathol* 2004;35:918–933.
42. Longacre TA, McKenney JK, Tazelaar HD, Kempson RL, Hendrickson MR. Ovarian serous tumors of low malignant potential (borderline tumors): outcome-based study of 276 patients with long-term (> or =5-year) follow-up. *Am J Surg Pathol* 2005;29:707–723.
43. Bell KA, Smith Sehdev AE, Kurman RJ. Refined diagnostic criteria for implants associated with ovarian atypical proliferative serous tumors (borderline) and micropapillary serous carcinomas. *Am J Surg Pathol* 2001;25:419–432.
44. McKenney JK, Gilks CB, Kalloger S, Longacre TA. Classification of Extraovarian Implants in Patients With Ovarian Serous Borderline Tumors (Tumors of Low Malignant Potential) Based on Clinical Outcome. *Am J Surg Pathol* 2016;40:1155–1164.
45. Ronnett BM, Kajdacsy-Balla A, Gilks CB, Merino MJ, Silva E, Werness BA *et al.* Mucinous borderline ovarian tumors: points of general agreement and persistent controversies regarding nomenclature, diagnostic criteria, and behavior. *Hum Pathol* 2004;35:949–960.

46. Carlson JW, Jarboe EA, Kindelberger D, Nucci MR, Hirsch MS, Crum CP. Serous tubal intraepithelial carcinoma: diagnostic reproducibility and its implications. *Int J Gynecol Pathol* 2010;29:310–314.
47. Visvanathan K, Vang R, Shaw P, Gross A, Soslow R, Parkash V *et al.* Diagnosis of serous tubal intraepithelial carcinoma based on morphologic and immunohistochemical features: a reproducibility study. *Am J Surg Pathol* 2011;35:1766–1775.
48. Leonhardt K, Einkenkel J, Sohr S, Engeland K, Horn LC. p53 signature and serous tubal in-situ carcinoma in cases of primary tubal and peritoneal carcinomas and serous borderline tumors of the ovary. *Int J Gynecol Pathol* 2011;30:417–424.
49. Kommos F, Faruqi A, Gilks CB, Lamshang Leen S, Singh N, Wilkinson N *et al.* Uterine Serous Carcinomas Frequently Metastasize to the Fallopian Tube and Can Mimic Serous Tubal Intraepithelial Carcinoma. *Am J Surg Pathol* 2017;41:161–170.
50. Rabban JT, Vohra P, Zaloudek CJ. Nongynecologic metastases to fallopian tube mucosa: a potential mimic of tubal high-grade serous carcinoma and benign tubal mucinous metaplasia or nonmucinous hyperplasia. *Am J Surg Pathol* 2015;39:35–51.
51. Singh N, Gilks CB, Hirshowitz L, Wilkinson N, McCluggage WG. Adopting a Uniform Approach to Site Assignment in Tubo-Ovarian High-Grade Serous Carcinoma: The Time has Come. *Int J Gynecol Pathol* 2016;35:230–237.
52. Fadare O. Recent developments on the significance and pathogenesis of lymph node involvement in ovarian serous tumors of low malignant potential (borderline tumors). *Int J Gynecol Cancer* 2009;19:103–108.
53. McKenney JK, Balzer BL, Longacre TA. Lymph node involvement in ovarian serous tumors of low malignant potential (borderline tumors): pathology, prognosis, and proposed classification. *Am J Surg Pathol* 2006;30:614–624.
54. Lee KR, Scully RE. Mucinous tumors of the ovary: a clinicopathologic study of 196 borderline tumors (of intestinal type) and carcinomas, including an evaluation of 11 cases with 'pseudomyxoma peritonei'. *Am J Surg Pathol* 2000;24:1447–1464.
55. Ludwick C, Gilks CB, Miller D, Yaziji H, Clement PB. Aggressive behavior of stage I ovarian mucinous tumors lacking extensive infiltrative invasion: a report of four cases and review of the literature. *Int J Gynecol Pathol* 2005;24:205–217.
56. Chang J, Sharpe JC, A'Hern RP, Fisher C, Blake P, Shepherd J *et al.* Carcinosarcoma of the ovary: incidence, prognosis, treatment and survival of patients. *Ann Oncol* 1995;6:755–758.
57. Harris MA, Delap LM, Sengupta PS, Wilkinson PM, Welch RS, Swindell R *et al.* Carcinosarcoma of the ovary. *Br J Cancer* 2003;88:654–657.
58. Bohm S, Faruqi A, Said I, Lockley M, Brockbank E, Jeyarajah A *et al.* Chemotherapy Response Score: Development and Validation of a System to Quantify Histopathologic Response to Neoadjuvant Chemotherapy in Tubo-Ovarian High-Grade Serous Carcinoma. *J Clin Oncol* 2015;33:2457–2463.
59. Said I, Bohm S, Beasley J, Ellery P, Faruqi AZ, Ganesan R *et al.* The Chemotherapy Response Score (CRS): Interobserver Reproducibility in a Simple and Prognostically Relevant System for Reporting the Histologic Response to Neoadjuvant Chemotherapy in Tuboovarian High-grade Serous Carcinoma. *Int J Gynecol Pathol* 2017;36:172–179.

60. Coghlan E, Meniawy TM, Munro A, Bulsara M, Stewart CJ, Tan A *et al*. Prognostic Role of Histological Tumor Regression in Patients Receiving Neoadjuvant Chemotherapy for High-Grade Serous Tubo-ovarian Carcinoma. *Int J Gynecol Cancer* 2017;27:708–713.
61. Lee JY, Chung YS, Na K, Kim HM, Park CK, Nam EJ *et al*. External validation of chemotherapy response score system for histopathological assessment of tumor regression after neoadjuvant chemotherapy in tubo-ovarian high-grade serous carcinoma. *J Gynecol Oncol* 2017;28:e73.
62. Lee SH, Kim H, Kim WY, Han KS, Lim SD, Kim S *et al*. Genetic alteration and immunohistochemical staining patterns of ovarian high grade serous adenocarcinoma with special emphasis on p53 immunostaining pattern. *Pathol Int* 2013;63:252–259.
63. Iwamoto M, Nakatani Y, Fugo K, Kishimoto T, Kiyokawa T. Napsin A is frequently expressed in clear cell carcinoma of the ovary and endometrium. *Hum Pathol* 2015;46:957–962.

**Appendix A WHO classification and SNOMED 'M' coding of surface epithelial neoplasms**

<b>Morphology</b>	<b>SNOMED 2/3 code</b>	<b>SNOMED CT terminology</b>	<b>SNOMED CT code</b>
<i>Serous tumours</i>			
Low-grade serous carcinoma	M84603	Low-grade serous carcinoma (morphologic abnormality)	703561001
High-grade serous carcinoma	M84413	High-grade serous carcinoma (morphologic abnormality)	703563003
Serous tubal intraepithelial carcinoma	M84412	Serous intraepithelial carcinoma (morphologic abnormality)	703558002
Serous borderline tumour	M84421	Serous cystadenoma, borderline malignancy (morphologic abnormality)	128849004
Serous borderline tumour, micropapillary variant	M84602	Serous borderline tumour, micropapillary variant (morphologic abnormality)	703559005
Serous cystadenoma	M84410	Serous cystadenoma (morphologic abnormality)	51608009
Serous adenofibroma	M90140	Serous adenofibroma (morphologic abnormality)	2026006
Serous surface papilloma	M84610	Serous surface papilloma (morphologic abnormality)	67073007
<i>Mucinous tumours</i>			
Mucinous carcinoma	M84803	Mucinous adenocarcinoma (morphologic abnormality)	72495009
Mucinous borderline tumour	M84721	Mucinous cystic tumour of borderline malignancy (morphologic abnormality)	128852007
Mucinous cystadenoma	M84700	Mucinous cystadenoma (morphologic abnormality)	67182003
Mucinous adenofibroma	M90150	Mucinous adenofibroma (morphologic abnormality)	10705005
<i>Endometrioid tumours</i>			
Endometrioid carcinoma	M83803	Endometrioid carcinoma (morphologic abnormality)	30289006
Endometrioid borderline tumour	M83801	Endometrioid adenoma, borderline malignancy (morphologic abnormality)	75987005
Endometriotic cyst	M76500	Endometriotic cyst (morphologic abnormality)	103678008
Endometrioid cystadenoma	M83800	Endometrioid adenoma (morphologic abnormality)	71106006

Endometrioid adenofibroma	M83810	Endometrioid adenofibroma (morphologic abnormality)	20829008
<i>Clear cell tumours</i>			
Clear cell carcinoma	M83103	Clear cell adenocarcinoma (morphologic abnormality)	30546008
Clear cell borderline tumour	M83103	Clear cell adenofibroma of borderline malignancy (morphologic abnormality)	128890001
Clear cell cystadenoma	M84430	Clear cell cystadenoma (morphologic abnormality)	128687009
Clear cell adenofibroma	M83130	Clear cell adenofibroma (morphologic abnormality)	58161009
<i>Brenner tumours</i>			
Malignant Brenner tumour	90003	Brenner tumour, malignant (morphologic abnormality)	42194009
Borderline Brenner tumour	90001	Brenner tumour, borderline malignancy (morphologic abnormality)	89996007
Brenner tumour	90000	Brenner tumour (morphologic abnormality)	74739000
<i>Seromucinous tumours</i>			
Seromucinous carcinoma	84743	Seromucinous carcinoma (morphologic abnormality)	703568007
Seromucinous borderline tumour	84741	Seromucinous borderline tumour (morphologic abnormality)	703565005
Seromucinous cystadenoma	84740	Seromucinous cystadenoma (morphologic abnormality)	703564009
Seromucinous adenofibroma	90140	Seromucinous adenofibroma (morphologic abnormality)	703652007
<i>Mixed epithelial tumours (specify components)</i>			
Malignant	M83233	Mixed cell adenocarcinoma (morphologic abnormality)	3895800
Borderline	M83231	Mixed epithelial tumour of borderline malignancy (morphologic abnormality)	399417005
Benign	M83230	Mixed cell adenoma (morphologic abnormality)	89773001
<i>Undifferentiated and unclassified tumours</i>			
Undifferentiated carcinoma	M80203	Carcinoma, undifferentiated (morphologic abnormality)	38549000
Adenocarcinoma, Not otherwise specified	M81403	Adenocarcinoma, no subtype (morphologic abnormality)	35917007



## Appendix B TNM and FIGO classification of tumours of the ovary and fallopian tube, and primary peritoneal carcinomas<sup>4</sup>

This classification applies to malignant surface epithelial-stromal tumours, including those of borderline malignancy.

TNM 7	TNM 8	FIGO stage	Descriptor
T – Primary tumour			
TX	TX		Primary tumour cannot be assessed
T0	T0		No evidence of primary tumour
T1	T1	I	Tumour limited to the ovaries or fallopian tube
T1a	T1a	IA	Tumour limited to one ovary (capsule intact) or fallopian tube, no tumour on ovarian or fallopian tube surface; no malignant cells in ascites or peritoneal washings
T1b	T1b	IB	Tumour limited to one or both ovaries (capsule intact) or fallopian tubes, no tumour on ovarian or fallopian tube surface; no malignant cells in ascites or peritoneal washings
T1c	T1c	IC	Tumour limited to one or both ovaries or fallopian tubes with or without any of the three criteria below:
	T1c1	IC1	• Surgical spill
	T1c2	IC2	• Capsule ruptured before surgery or tumour on ovarian or fallopian tube surface
	T1c3	IC3	• Malignant cells in ascites or peritoneal washings
T2	T2	II	Tumour involves one or both ovaries or fallopian tubes with pelvic extension (below the pelvic brim) or primary peritoneal carcinoma
T2a	T2a	IIA	Extension and/or implants on uterus and/or fallopian tube(s) and/or ovaries
T2b	T2b	IIB	Extension to other pelvic tissues, including bowel serosa within the pelvis
T3 and/or N1	T3 and/or N1	III	Tumour involves one or both ovaries or fallopian tubes or primary peritoneal carcinoma with microscopically confirmed peritoneal metastases outside the pelvis and/or regional lymph node metastasis (includes liver capsular metastasis)
T3a	T3a	IIIA2	Microscopic peritoneal metastasis beyond pelvis, with or without retroperitoneal lymph node involvement
T3b	T3b	IIIB	Macroscopic peritoneal metastasis beyond pelvis, 2 cm or less in greatest dimension, with or without retroperitoneal lymph node involvement, including bowel involvement
T3c and/or N1	T3c	IIIC	Peritoneal metastasis beyond pelvis more than 2 cm in greatest dimension with or without retroperitoneal lymph node involvement
M1	M1	IV	Distant metastasis (excludes peritoneal and liver

			capsular metastasis, includes inguinal lymph nodes and lymph nodes outside the peritoneal cavity)
M1a	M1a	IVA	Pleural effusion with positive cytology
<b>TNM 7</b>	<b>TNM 8</b>	<b>FIGO stage</b>	<b>Descriptor</b>
M1b	M1b	IVB	Parenchymal metastasis and metastasis to extra-abdominal organs

TNM 7	TNM 8	FIGO stage	Descriptor
N – Regional lymph nodes*			
NX			Regional lymph nodes cannot be assessed
N0			No regional lymph node metastasis
N1	N1	IIIA1	Regional lymph node metastasis
N1a	N1a	IIIAi	Lymph node metastasis not more than 10 mm in greatest dimension
N1b	N1b	IIIAii	Lymph node metastasis more than 10 mm in greatest dimension

TNM 7	TNM 8	FIGO stage	Descriptor
M – Distant metastasis**			
MX			Distant metastasis cannot be assessed
M0			No distant metastasis
M1	M1	IV	Distant metastasis (excludes peritoneal metastasis)
	M1a	IVA	Pleural effusion with positive cytology
	M1b	IVB	Parenchymal metastasis and metastasis to extra-abdominal organs (including inguinal lymph nodes and lymph nodes outside abdominal cavity)

## Notes

\*Regional lymph nodes are: hypogastric (obturator), common iliac, external iliac, lateral sacral, para-aortic and retroperitoneal lymph nodes.

\*\*Liver capsule metastasis is T3/stage III; liver and splenic parenchymal metastases are M1/stage IV; transmural invasion of the bowel wall with mucosal involvement is classified as M1/stage IV;<sup>3</sup> and pleural effusions must have positive cytology for confirmation of M1/stage IV.

## **Appendix C      Guide to use of immunohistochemistry in tubo-ovarian carcinomas**

This appendix is intended as a non-exhaustive guide to aid classification of carcinomas of ovarian, tubal and primary peritoneal origin in difficult cases, or in cases of small biopsy specimens.

As in all cases, the general tenets of immunohistochemistry interpretation apply. One should always use immunostains as part of a panel, and know the normal staining pattern and compartment of the cell that should be positive. Internal controls are mandatory, especially in cases where one is looking for loss of expression (e.g. mismatch repair [MMR] immunohistochemistry, null pattern p53 staining). In general, diagnosis should not be based on the result of a single immunostain and should always be based primarily on morphology, supported by ancillary tests. Unexpected positive and negative staining reactions may occur, and results should always be interpreted in conjunction with the clinical, radiological and morphological features as part of a multidisciplinary approach.

### **High-grade ovarian carcinomas**

In some cases, it may be difficult to differentiate between high-grade endometrioid and high-grade serous carcinomas. Furthermore, high-grade serous carcinomas may contain large areas with clear cell morphology.

A combination of diffuse WT1 positivity and mutant-type p53 immunostaining is corroborative of a diagnosis of high-grade serous carcinoma, while negative or only focal WT1 expression and wild-type p53 immunoreactivity together with oestrogen receptor (ER) and progesterone receptor positivity would suggest endometrioid carcinoma.<sup>32,35</sup> Other softer signs such as background endometriosis may assist in the diagnosis. In addition, p16 staining is often diffusely positive in high-grade serous carcinomas, but only shows patchy expression in endometrioid carcinoma.<sup>62</sup> A small proportion of grade 3 endometrioid carcinomas may show a mutant p53 immunophenotype. ER testing is not helpful in distinguishing serous from endometrioid histotypes, as many high-grade serous carcinomas of tubo-ovarian origin are diffusely ER positive.

Clear cell carcinomas show a wild-type p53 pattern, napsin A positivity, and are negative for WT1 and ER.<sup>63</sup>

Use of MMR immunohistochemistry may aid diagnosis,<sup>10</sup> as well as providing prognostic information and the opportunity for future therapeutic options such as immunotherapy. The absence of expression of one or more of the proteins MLH1, PMS2, MSH2 or MSH6 indicates high microsatellite instability and is corroborative of a diagnosis of endometrioid or clear cell carcinoma rather than serous carcinoma (which have different underlying molecular pathways).

### **High-grade versus low-grade serous carcinoma**

This may occasionally be problematic in a biopsy specimen. High-grade serous carcinoma shows a mutant p53 immunophenotype in approximately 95% of cases and this is the most helpful distinguishing feature. Other helpful immunostains include p16 (which often shows diffuse positive staining in high-grade serous carcinoma) and Ki67 (which should be moderate to high in high-grade serous carcinoma and show much lower proliferation indices in low-grade serous carcinoma). WT1 will be positive in both subtypes. ER testing is unhelpful in this situation.

### **Mucinous carcinomas: differentiation between primary and metastatic**

Differentiation between primary and metastatic mucinous carcinoma is important as it has significant prognostic implications, but it may be difficult based on immunohistochemistry alone. This is because intestinal-type primary mucinous ovarian carcinomas have an enteric phenotype

and may express markers such as CDX2 and CA19.9. Correlation with clinical and radiological features, together with morphological findings such as extensive destructive stromal invasion or pseudomyxoma ovarii, is therefore imperative.

However, immunohistochemical features reported to be helpful in this situation are CK7 and CK20, with a CK7+/CK20- phenotype being consistent with an ovarian primary. DPC4 is a marker that is deleted in approximately 50% of pancreatic adenocarcinomas; loss of expression of this marker is very helpful as the vast majority of primary ovarian carcinomas show retention of DPC4 expression.

Although unusual, metastatic cervical adenocarcinoma may mimic a primary mucinous borderline tumour or carcinoma and therefore addition of p16 to the immunopanel in this setting is suggested. Block positivity raises the possibility of an occult human papillomavirus-associated cervical primary.

### **Reassigning seromucinous carcinomas**

As described above, the validity of the diagnosis of seromucinous carcinoma has been called into question<sup>34</sup> and thus we recommend, where possible, assigning tumours that may previously have fallen into this category into endometrioid or low-grade serous subtypes. Please note that true seromucinous borderline tumours are still considered to represent a distinct entity and should be diagnosed appropriately. As they often arise in a background of endometriosis, the presence of other components such as clear cell carcinoma as a component of a mixed carcinoma should also be excluded, especially as endometrioid adenocarcinoma/clear cell carcinoma appears to be the most common combination<sup>33</sup> in mixed tumours.

The majority of these cases will be reclassified as endometrioid carcinoma, using a combination of morphological and immunophenotypic assessment. They may show prominent mucinous differentiation. Extensive tumour cell immunopositivity for WT1 is consistent with a diagnosis of low-grade serous carcinoma. Immunohistochemistry for p53 and ER will not be helpful for distinction between these two subtypes, as both show wild-type staining for p53 and ER positivity. Immunohistochemistry for MMR proteins may be useful for diagnosis of endometrioid adenocarcinoma.

## Appendix D Reporting proforma for ovarian, tubal and primary peritoneal carcinomas

Surname: ..... Forenames: ..... Date of birth: .....  
 Patient identifier (CHI/NHS no): ..... Hospital: ..... Hospital no: .....  
 Date of surgery: ..... Date of receipt: ..... Date of reporting: .....  
 Report no: ..... Pathologist: ..... Surgeon: .....

### PRIOR CHEMOTHERAPY†

No chemotherapy required  Prior chemotherapy administered  Not known

### SPECIMEN TYPE† (Select all that apply)

Right ovary  Right ovarian cystectomy  Right fallopian tube   
 Left ovary  Left ovarian cystectomy  Left fallopian tube   
 Uterus  Cervix  Omentum   
 Peritoneal biopsies  Peritoneal washings/ascitic fluid   
 Lymph nodes (specify site/s) .....   
 Other e.g. bowel, bladder, appendix (specify) .....

### SPECIMEN INTEGRITY (Required only if ovary(ies)/fallopian tubes are submitted)

<b>Right ovary†</b>		<b>Left ovary†</b>	
Ovarian capsule intact	<input type="checkbox"/>	Ovarian capsule intact	<input type="checkbox"/>
Ovarian capsule ruptured	<input type="checkbox"/>	Ovarian capsule ruptured	<input type="checkbox"/>
Tumour on surface	<input type="checkbox"/>	Tumour on surface	<input type="checkbox"/>
Fragmented specimen	<input type="checkbox"/>	Fragmented specimen	<input type="checkbox"/>
Other .....	<input type="checkbox"/>	Other .....	<input type="checkbox"/>
<b>Right fallopian tube</b>		<b>Left fallopian tube</b>	
Serosa intact	<input type="checkbox"/>	Serosa intact	<input type="checkbox"/>
Serosa ruptured	<input type="checkbox"/>	Serosa ruptured	<input type="checkbox"/>
Tumour on serosal surface	<input type="checkbox"/>	Tumour on serosal surface	<input type="checkbox"/>
Fragmented specimen	<input type="checkbox"/>	Fragmented specimen	<input type="checkbox"/>
Other.....	<input type="checkbox"/>	Other.....	<input type="checkbox"/>

### MACROSCOPIC TUMOUR SITE (Select all that apply)

Right ovary	<input type="checkbox"/>	Right fallopian tube	<input type="checkbox"/>	Left fallopian tube	<input type="checkbox"/>
Left ovary	<input type="checkbox"/>	Fimbrial	<input type="checkbox"/>	Fimbrial	<input type="checkbox"/>
Peritoneum	<input type="checkbox"/>	Non-fimbrial	<input type="checkbox"/>	Non-fimbrial	<input type="checkbox"/>
Omentum	<input type="checkbox"/>				<input type="checkbox"/>
Other (specify)	<input type="checkbox"/>				
Indeterminate	<input type="checkbox"/>				

### MACROSCOPIC DESCRIPTION OF OMENTUM (Required only if omentum submitted)

Omentum dimensions ..... mm x ..... mm x ..... mm  
 Omental involvement Involved  Not involved   
 Maximum dimension of largest deposit ..... mm

### HISTOLOGICAL TUMOUR TYPE AND GRADE†

(Note: If chemotherapy has been administered the grading may need to be based on the pre-chemotherapy biopsy)

**Serous carcinomas**  
 Low grade  Cannot be graded   
 High grade

**Endometrioid carcinomas**  
 G1: Well differentiated  G3: Poorly differentiated   
 G2: Moderately differentiated  GX: Cannot be graded

**Clear cell carcinomas**  **Carcinosarcoma**   
 High grade  High grade

**Undifferentiated carcinomas**

High grade

**Mucinous carcinomas**

G1: Well differentiated  G3: Poorly differentiated

G2: Moderately differentiated  GX: Cannot be graded

**Mixed epithelial types**

**Other**

Specify (if Other or Mixed epithelial types)

**BORDERLINE TUMOUR**

Present  Absent

**Histological tumour type**

**SEROUS TUBAL INTRAEPITHELIAL CARCINOMA (STIC)**

*(Required only if fallopian tube(s) are submitted and applicable to high-grade serous carcinoma only)*

**Right fallopian tube**

Present – fimbrial

Present – non-fimbrial

Not identified

Cannot be assessed

**Left fallopian tube**

Present – fimbrial

Present – non-fimbrial

Not identified

Cannot be assessed

**HISTOLOGICAL SITES OF TUMOUR INVOLVEMENT**

**Right ovary<sup>†</sup>**

Not involved  Cannot be assessed

Involved  Not applicable

**Left ovary<sup>†</sup>**

Not involved  Cannot be assessed

Involved  Not applicable

**Right ovarian capsule/surface<sup>†</sup>**

Not involved  Cannot be assessed

Involved  Not applicable

**Left ovarian capsule/surface<sup>†</sup>**

Not involved  Cannot be assessed

Involved  Not applicable

**Right fallopian tube<sup>†</sup>**

Not involved  Cannot be assessed

Involved  Not applicable

**Left fallopian tube<sup>†</sup>**

Not involved  Cannot be assessed

Involved  Not applicable

**Uterus**

Not involved  Cannot be assessed

Involved  Not applicable

Site(s):

Myometrium  Endometrium  Cervix

**Omentum<sup>†</sup>**

Not involved  Cannot be assessed

Involved  Not applicable

Level of involvement:

Macroscopic  Microscopic

**Peritoneum (including uterine serosa)<sup>†</sup>**

Not involved  Cannot be assessed

Involved  Not applicable

Site(s):

Pelvis (specify site/s)

Abdomen (specify site/s)

**Other involved organ(s)/site(s) (specify)**

**PERITONEAL CYTOLOGY<sup>†</sup>**

Negative  Indeterminate

Positive  Not received

**LYMPH NODE STATUS†**

Not submitted  Not involved  Involved

**Regional**

**Left pelvic**

Number of lymph nodes examined\*\*

Number of positive lymph nodes\*\*

**Right pelvic**

Number of lymph nodes examined\*\*

Number of positive lymph nodes\*\*

**Para-aortic**

Number of lymph nodes examined\*\*

Number of positive lymph nodes\*\*


**Maximum dimension of largest deposit in regional node** ..... mm

**Non-regional**

**Site 1**

Number of lymph nodes examined\*\*

Number of positive lymph nodes\*\*

**Site 2**

Number of lymph nodes examined\*\*

Number of positive lymph nodes\*\*


*Note:*

\*\*In some cases, it may not be possible to record the actual number of nodes owing to fragmentation of the specimen.

**SITE OF TUMOUR†**

Primary tumour, ovary  Primary tumour, peritoneum

Primary tumour, fallopian tube  Undesignated: site of primary tumour cannot be assessed

**Comments:**

**Provisional FIGO stage†** ..... (may change following MDTM discussion)

**SNOMED codes†: T..... M.....**

**Pathologist:** .....

**Date:**

*Note:*

†Data items that are currently part of the Cancer Outcomes and Services Dataset (COSD) version 8.

## Appendix E Reporting proforma for ovarian, tubal and primary peritoneal borderline tumours

Surname: ..... Forenames: ..... Date of birth: .....  
 Patient identifier (CHI/NHS no): ..... Hospital: ..... Hospital no: .....  
 Date of surgery: ..... Date of receipt: ..... Date of reporting: .....  
 Report no: ..... Pathologist: ..... Surgeon: .....

### SPECIMEN TYPE<sup>†</sup> (Select all that apply)

Right ovary	<input type="checkbox"/>	Right ovarian cystectomy	<input type="checkbox"/>	Right fallopian tube	<input type="checkbox"/>
Left ovary	<input type="checkbox"/>	Left ovarian cystectomy	<input type="checkbox"/>	Left fallopian tube	<input type="checkbox"/>
Uterus	<input type="checkbox"/>	Cervix	<input type="checkbox"/>	Omentum	<input type="checkbox"/>
Peritoneal biopsies	<input type="checkbox"/>	Peritoneal washings/ascitic fluid			<input type="checkbox"/>
Lymph nodes (specify site/s) .....					<input type="checkbox"/>
Other e.g. bowel, bladder, appendix (specify) .....					<input type="checkbox"/>

### SPECIMEN INTEGRITY (Required only if ovary[ies]/fallopian tubes are submitted)

<b>Right ovary<sup>†</sup></b>		<b>Left ovary<sup>†</sup></b>	
Ovarian capsule intact	<input type="checkbox"/>	Ovarian capsule intact	<input type="checkbox"/>
Ovarian capsule ruptured	<input type="checkbox"/>	Ovarian capsule ruptured	<input type="checkbox"/>
Tumour on surface	<input type="checkbox"/>	Tumour on surface	<input type="checkbox"/>
Fragmented specimen	<input type="checkbox"/>	Fragmented specimen	<input type="checkbox"/>
Other .....	<input type="checkbox"/>	Other .....	<input type="checkbox"/>
<b>Right fallopian tube</b>		<b>Left fallopian tube</b>	
Serosa intact	<input type="checkbox"/>	Serosa intact	<input type="checkbox"/>
Serosa ruptured	<input type="checkbox"/>	Serosa ruptured	<input type="checkbox"/>
Tumour on serosal surface	<input type="checkbox"/>	Tumour on serosal surface	<input type="checkbox"/>
Fragmented specimen	<input type="checkbox"/>	Fragmented specimen	<input type="checkbox"/>
Other.....	<input type="checkbox"/>	Other.....	<input type="checkbox"/>

### MACROSCOPIC TUMOUR SITE (Select all that apply)

Right ovary	<input type="checkbox"/>	Right fallopian tube	<input type="checkbox"/>	Left fallopian tube	<input type="checkbox"/>
Left ovary	<input type="checkbox"/>	Fimbrial	<input type="checkbox"/>	Fimbrial	<input type="checkbox"/>
Peritoneum	<input type="checkbox"/>	Non-fimbrial	<input type="checkbox"/>	Non-fimbrial	<input type="checkbox"/>
Omentum	<input type="checkbox"/>				<input type="checkbox"/>
Other (specify)	<input type="checkbox"/>				
Indeterminate	<input type="checkbox"/>				

### MACROSCOPIC DESCRIPTION OF OMENTUM (Required only if omentum submitted)

Omentum dimensions ..... mm x ..... mm x ..... mm  
 Omental involvement Involved  Not involved   
 Maximum dimension of largest deposit ..... mm

### HISTOLOGICAL TUMOUR TYPE AND GRADE<sup>†</sup>

(Note: If chemotherapy has been administered the grading may need to be based on the pre-chemotherapy biopsy)

Serous	<input type="radio"/>	Mucinous	<input type="radio"/>
Serous micropapillary variant	<input type="radio"/>	Endometrioid	<input type="radio"/>
		Clear cell	<input type="radio"/>
Mixed epithelial types	<input type="radio"/>	Other	<input type="radio"/>
Specify (if Other or Mixed epithelial types)	<input type="radio"/>		

### IMPLANTS FOR SEROUS & SEROMUCINOUS BORDERLINE TUMOUR

<b>Non-invasive implants</b>	Not identified	<input type="radio"/>
	Present, Epithelial	<input type="radio"/>
	Present, Desmoplastic	<input type="radio"/>
	If present, Pelvic <input type="checkbox"/> Abdominal <input type="checkbox"/>	<input type="radio"/>
		<input type="radio"/>



**Invasive implants/Extra-ovarian low-grade serous carcinoma**

Not identified  
Present  
If present, Pelvic  Abdominal

**Indeterminate**

Not identified   
Present   
If present, Pelvic  Abdominal

**HISTOLOGICAL SITES OF TUMOUR INVOLVEMENT**

**Right ovary<sup>†</sup>**

Not involved  Cannot be assessed   
Involved  Not applicable

**Left ovary<sup>†</sup>**

Not involved  Cannot be assessed   
Involved  Not applicable

**Right ovarian capsule/surface<sup>†</sup>**

Not involved  Cannot be assessed   
Involved  Not applicable

**Left ovarian capsule/surface<sup>†</sup>**

Not involved  Cannot be assessed   
Involved  Not applicable

**Right fallopian tube<sup>†</sup>**

Not involved  Cannot be assessed   
Involved  Not applicable

**Left fallopian tube<sup>†</sup>**

Not involved  Cannot be assessed   
Involved  Not applicable

**Uterus**

Not involved  Cannot be assessed   
Involved  Not applicable

Site(s):

Myometrium  Endometrium  Cervix

**Omentum<sup>†</sup>**

Not involved  Cannot be assessed   
Involved  Not applicable

Level of involvement:

Macroscopic  Microscopic

**Peritoneum (including uterine serosa)<sup>†</sup>**

Not involved  Cannot be assessed   
Involved  Not applicable

Site(s):

Pelvis (specify site/s)

Abdomen (specify site/s)

**Other involved organ(s)/site(s) (specify)**

**PERITONEAL CYTOLOGY<sup>†</sup>**

Negative  Indeterminate   
Positive  Not received

**LYMPH NODE STATUS<sup>†</sup>**

Not submitted  Not involved  Involved

**Regional**

**Left pelvic**

Number of lymph nodes examined\*\*

Number of positive lymph nodes\*\*

**Right pelvic**

Number of lymph nodes examined\*\*

Number of positive lymph nodes\*\*

**Para-aortic**

Number of lymph nodes examined\*\*

Number of positive lymph nodes\*\*

**Non-regional**

**Site 1**

Number of lymph nodes examined\*\*

Number of positive lymph nodes\*\*

**Site 2**

Number of lymph nodes examined\*\*

Number of positive lymph nodes\*\*


*Note:*

\*\*In some cases, it may not be possible to record the actual number of nodes owing to fragmentation of the specimen.

**SITE OF TUMOUR†**

Primary tumour, ovary

Primary tumour, fallopian tube

Primary tumour, peritoneum

Undesignated: site of primary tumour cannot be assessed

**Comments:**

**Provisional FIGO stage†**

.....

*(may change following MDTM discussion)*

**SNOMED codes†: T..... M.....**

**Pathologist:** .....  
...../...../.....

**Date:**

*Note:*

†Data items that are currently part of the Cancer Outcomes and Services Dataset (COSD) version 8.

**Appendix F Reporting proforma for ovarian, tubal and primary peritoneal carcinomas in list format**

<b>Element name</b>	<b>Values</b>	<b>Implementation notes</b>
Prior chemotherapy	Single selection value list: <ul style="list-style-type: none"> <li>No chemotherapy required</li> <li>Prior chemotherapy administered</li> <li>Not known</li> </ul>	
Specimen type	Multiple selection value list: <ul style="list-style-type: none"> <li>Right ovary</li> <li>Right ovarian cystectomy</li> <li>Right fallopian tube</li> <li>Left ovary</li> <li>Left ovarian cystectomy</li> <li>Left fallopian tube</li> <li>Uterus</li> <li>Cervix</li> <li>Omentum</li> <li>Peritoneal biopsies</li> <li>Peritoneal washings/ascitic fluid</li> <li>Lymph nodes</li> <li>Other</li> </ul>	
Specimen type, Lymph nodes, specify	Free text	Only applicable if 'Specimen type, Lymph nodes' is selected.
Specimen type, Other, specify	Free text	Only applicable if 'Specimen type, Other' is selected.
Specimen integrity, Right ovary	Multiple selection value list: <ul style="list-style-type: none"> <li>Ovarian capsule intact</li> <li>Ovarian capsule ruptured</li> <li>Tumour on surface</li> <li>Fragmented specimen</li> <li>Other</li> </ul>	Only applicable if 'Specimen type, Right ovary' or 'Specimen type, Right ovarian cystectomy' is selected.
Specimen integrity, Right ovary, Other	Free text	Only applicable if 'Specimen integrity, Right ovary, Other' is selected.
Specimen integrity, Left ovary	Multiple selection value list: <ul style="list-style-type: none"> <li>Ovarian capsule intact</li> <li>Ovarian capsule ruptured</li> <li>Tumour on surface</li> <li>Fragmented specimen</li> <li>Other</li> </ul>	Only applicable if 'Specimen type, Left ovary' or 'Specimen type, Left ovarian cystectomy' is selected.
Specimen integrity, Left ovary, Other	Free text	Only applicable if

		'Specimen integrity, Left ovary, Other' is selected.
Specimen integrity, Right fallopian tube	Multiple selection value list: <ul style="list-style-type: none"> <li>• Serosa intact</li> <li>• Serosa ruptured</li> <li>• Tumour on serosal surface</li> <li>• Fragmented specimen</li> <li>• Other</li> </ul>	Only applicable if 'Specimen type, Right fallopian tube' is selected.
Specimen integrity, Right fallopian tube, Other	Free text	Only applicable if 'Specimen integrity, Right fallopian tube, Other' is selected.
Specimen integrity, Left fallopian tube	Multiple selection value list: <ul style="list-style-type: none"> <li>• Serosa intact</li> <li>• Serosa ruptured</li> <li>• Tumour on serosal surface</li> <li>• Fragmented specimen</li> <li>• Other</li> </ul>	Only applicable if 'Specimen type, Left fallopian tube' is selected.
Specimen integrity, Left fallopian tube, Other	Free text	Only applicable if 'Specimen integrity, Left fallopian tube, Other' is selected.
Macroscopic tumour site	Multiple selection value list: <ul style="list-style-type: none"> <li>• Right ovary</li> <li>• Right fallopian tube</li> <li>• Left ovary</li> <li>• Left fallopian tube</li> <li>• Omentum</li> <li>• Peritoneum</li> <li>• Other</li> <li>• Indeterminate</li> </ul>	
Macroscopic tumour site, Right fallopian tube	Multiple selection value list: <ul style="list-style-type: none"> <li>• Fimbrial</li> <li>• Non-fimbrial</li> </ul>	Only applicable if 'Macroscopic tumour site, Right fallopian tube' is selected.
Macroscopic tumour site, Left fallopian tube	Multiple selection value list: <ul style="list-style-type: none"> <li>• Fimbrial</li> <li>• Non-fimbrial</li> </ul>	Only applicable if 'Macroscopic tumour site, Left fallopian tube' is selected.
Macroscopic tumour site, Other	Free text	Only applicable if 'Macroscopic tumour site, Other' is selected.
Omentum dimension 1	Size in mm	
Omentum dimension 2	Size in mm	
Omentum dimension 3	Size in mm	
Omental involvement	Single selection value list: <ul style="list-style-type: none"> <li>• Involved</li> </ul>	

	<ul style="list-style-type: none"> <li>• Not involved</li> </ul>	
Omentum, Maximum dimension of largest deposit	Size in mm	
Histological tumour type and grade	<p>Single selection value list:</p> <ul style="list-style-type: none"> <li>• Serous carcinoma, low grade</li> <li>• Serous carcinoma, high grade</li> <li>• Serous carcinoma, cannot be graded</li> <li>• Endometrioid carcinoma, G1</li> <li>• Endometrioid carcinoma, G2</li> <li>• Endometrioid carcinoma, G3</li> <li>• Endometrioid carcinoma, GX</li> <li>• Clear cell carcinoma, high grade</li> <li>• Carcinosarcoma, high grade</li> <li>• Undifferentiated carcinoma, high grade</li> <li>• Mucinous carcinoma, G1</li> <li>• Mucinous carcinoma, G2</li> <li>• Mucinous carcinoma, G3</li> <li>• Mucinous carcinoma, GX</li> <li>• Mixed epithelial subtypes</li> <li>• Other</li> </ul>	
Histological tumour type and grade, Specify	Free text	Only applicable if 'Histological type and grade, Mixed epithelial types' or 'Histological type and grade, Other' is selected.
Borderline tumour	<p>Single selection value list:</p> <ul style="list-style-type: none"> <li>• Present</li> <li>• Absent</li> </ul>	
Borderline tumour, Histological tumour type	Free text	Only applicable if 'Borderline tumour, Present' is selected.
Serous tubal intraepithelial carcinoma, Right fallopian tube	<p>Single selection value list:</p> <ul style="list-style-type: none"> <li>• Present – fimbrial</li> <li>• Present – non-fimbrial</li> <li>• Not identified</li> <li>• Cannot be assessed</li> </ul>	Only applicable if 'Specimen type' includes 'Right fallopian tube' and 'Histological tumour type and grade, Serous carcinoma, High grade' is selected.
Serous tubal intraepithelial carcinoma, Left fallopian tube	<p>Single selection value list:</p> <ul style="list-style-type: none"> <li>• Present – fimbrial</li> <li>• Present – non-fimbrial</li> </ul>	Only applicable if 'Specimen type' includes 'Left fallopian tube' and 'Histological tumour type

	<ul style="list-style-type: none"> <li>• Not identified</li> <li>• Cannot be assessed</li> </ul>	and grade, Serous carcinoma, High grade' is selected.
Histological sites of tumour involvement, Right ovary	<p>Single selection value list:</p> <ul style="list-style-type: none"> <li>• Not involved</li> <li>• Involved</li> <li>• Cannot be assessed</li> <li>• Not applicable</li> </ul>	Not applicable if 'Specimen type' does not include 'Right ovary' or 'Right ovarian cystectomy'.
Histological sites of tumour involvement, Left ovary	<p>Single selection value list:</p> <ul style="list-style-type: none"> <li>• Not involved</li> <li>• Involved</li> <li>• Cannot be assessed</li> <li>• Not applicable</li> </ul>	Not applicable if 'Specimen type' does not include 'Left ovary' or 'Left ovarian cystectomy'.
Histological sites of tumour involvement, Right ovarian capsule/surface	<p>Single selection value list:</p> <ul style="list-style-type: none"> <li>• Not involved</li> <li>• Involved</li> <li>• Cannot be assessed</li> <li>• Not applicable</li> </ul>	Not applicable if 'Specimen type' does not include 'Right ovary' or 'Right ovarian cystectomy'.
Histological sites of tumour involvement, Left ovarian capsule/surface	<p>Single selection value list:</p> <ul style="list-style-type: none"> <li>• Not involved</li> <li>• Involved</li> <li>• Cannot be assessed</li> <li>• Not applicable</li> </ul>	Not applicable if 'Specimen type' does not include 'Left ovary' or 'Left ovarian cystectomy'.
Histological sites of tumour involvement, Right fallopian tube	<p>Single selection value list:</p> <ul style="list-style-type: none"> <li>• Not involved</li> <li>• Involved</li> <li>• Cannot be assessed</li> <li>• Not applicable</li> </ul>	Not applicable if 'Specimen type' does not include 'Right fallopian tube'.
Histological sites of tumour involvement, Left fallopian tube	<p>Single selection value list:</p> <ul style="list-style-type: none"> <li>• Not involved</li> <li>• Involved</li> <li>• Cannot be assessed</li> <li>• Not applicable</li> </ul>	Not applicable if 'Specimen type' does not include 'Left fallopian tube'.
Histological sites of tumour involvement, Uterus	<p>Single selection value list:</p> <ul style="list-style-type: none"> <li>• Not involved</li> <li>• Involved</li> <li>• Cannot be assessed</li> <li>• Not applicable</li> </ul>	Not applicable if 'Specimen type' does not include 'Uterus'.
Histological sites of tumour involvement, Uterus, Site(s)	<p>Multiple selection value list:</p> <ul style="list-style-type: none"> <li>• Myometrium</li> <li>• Endometrium</li> <li>• Cervix</li> </ul>	Only applicable if 'Histological sites of tumour involvement, Uterus, Involved' is selected.
Histological sites of tumour involvement, Omentum	<p>Single selection value list:</p> <ul style="list-style-type: none"> <li>• Not involved</li> <li>• Involved</li> <li>• Cannot be assessed</li> </ul>	Not applicable if 'Specimen type' does not include 'Omentum'.

	<ul style="list-style-type: none"> <li>• Not applicable</li> </ul>	
Histological sites of tumour involvement, Omentum, Level of involvement	Single selection value list: <ul style="list-style-type: none"> <li>• Microscopic</li> <li>• Macroscopic</li> </ul>	Only applicable if 'Histological sites of tumour involvement, Omentum, Involved' is selected.
Histological sites of tumour involvement, Peritoneum (including uterine serosa)	Single selection value list: <ul style="list-style-type: none"> <li>• Not involved</li> <li>• Involved</li> <li>• Cannot be assessed</li> <li>• Not applicable</li> </ul>	Not applicable if 'Specimen type' does not include 'Peritoneal biopsies'.
Histological sites of tumour involvement, Peritoneum (including uterine serosa), Site(s)	Multiple selection value list: <ul style="list-style-type: none"> <li>• Pelvis</li> <li>• Abdomen</li> </ul>	Only applicable if 'Histological sites of tumour involvement, Peritoneum (including uterine serosa), Involved' is selected.
Histological sites of tumour involvement, Peritoneum (including uterine serosa), Site(s), Pelvis, specify	Free text	Only applicable if 'Histological sites of tumour involvement, Peritoneum (including uterine serosa), Site(s), Pelvis' is selected.
Histological sites of tumour involvement, Peritoneum (including uterine serosa), Site(s), Abdomen, specify	Free text	Only applicable if 'Histological sites of tumour involvement, Peritoneum (including uterine serosa), Site(s), Abdomen' is selected.
Other involved organ(s)/site(s)	Free text	
Peritoneal cytology	Single selection value list: <ul style="list-style-type: none"> <li>• Negative</li> <li>• Positive</li> <li>• Indeterminate</li> <li>• Not received</li> </ul>	
Lymph node status	Single selection value list: <ul style="list-style-type: none"> <li>• Not submitted</li> <li>• Not involved</li> <li>• Involved</li> </ul>	
Regional lymph nodes, Left pelvic, Number of lymph nodes examined	Integer	Not applicable if 'Lymph node status, Not submitted' is selected.
Regional lymph nodes, Left pelvic, Number of positive lymph nodes	Integer	Not applicable if 'Lymph node status, Not submitted' is selected or 'Regional lymph nodes, Left pelvic, Number of lymph nodes examined' is <1.
Regional lymph nodes, Right pelvic, Number of lymph nodes examined	Integer	Not applicable if 'Lymph node status, Not submitted' is selected.

Regional lymph nodes, Right pelvic, Number of positive lymph nodes	Integer	Not applicable if 'Lymph node status, Not submitted' is selected or 'Regional lymph nodes, Right pelvic, Number of lymph nodes examined' is <1.
Regional lymph nodes, Para-aortic, Number of lymph nodes examined	Integer	Not applicable if 'Lymph node status, Not submitted' is selected.
Regional lymph nodes, Para-aortic, Number of positive lymph nodes	Integer	Not applicable if 'Lymph node status, Not submitted' is selected or 'Regional lymph nodes, Para-aortic, Number of lymph nodes examined' is <1.
Maximum dimension of largest deposit in regional node	Size in mm	Not applicable if 'Lymph node status, Not submitted' is selected.
Non-regional lymph node, Site 1	Free text	Not applicable if 'Lymph node status, Not submitted' is selected.
Non-regional lymph nodes, Site 1, Number of lymph nodes examined	Integer	Not applicable if 'Lymph node status, Not submitted' is selected.
Non-regional lymph nodes, Site 1, Number of positive lymph nodes	Integer	Not applicable if 'Lymph node status, Not submitted' is selected or 'Non-regional lymph nodes, Site 1, Number of lymph nodes examined' is <1.
Non-regional lymph node, Site 2	Free text	Not applicable if 'Lymph node status, Not submitted' is selected.
Non-regional lymph nodes, Site 2, Number of lymph nodes examined	Integer	Not applicable if 'Lymph node status, Not submitted' is selected.
Non-regional lymph nodes, Site 2, Number of positive lymph nodes	Integer	Not applicable if 'Lymph node status, Not submitted' is selected or 'Non-regional lymph nodes, Site 2, Number of lymph nodes examined' is <1.
Site of tumour	Single selection value list: <ul style="list-style-type: none"> <li>• Primary tumour, ovary</li> <li>• Primary tumour, fallopian tube</li> <li>• Primary tumour, peritoneum</li> <li>• Undesignated: site of primary tumour cannot be assessed</li> </ul>	



Comments	Free text	
Provisional FIGO stage	Single selection value list: <ul style="list-style-type: none"> <li>• IA</li> <li>• IB</li> <li>• IC1</li> <li>• IC2</li> <li>• IC3</li> <li>• IIA</li> <li>• IIB</li> <li>• IIIA1i</li> <li>• IIIA1ii</li> <li>• IIIA2</li> <li>• IIIB</li> <li>• IIIC</li> <li>• IVA</li> <li>• IVB</li> </ul>	
SNOMED T code	May have multiple codes. Look up from SNOMED tables.	
SNOMED M code	May have multiple codes. Look up from SNOMED tables.	

**Appendix G Reporting proforma for ovarian, tubal and primary peritoneal borderline tumours in list format**

<b>Element name</b>	<b>Values</b>	<b>Implementation notes</b>
Specimen type	Multiple selection value list: <ul style="list-style-type: none"> <li>• Right ovary</li> <li>• Right ovarian cystectomy</li> <li>• Right fallopian tube</li> <li>• Left ovary</li> <li>• Left ovarian cystectomy</li> <li>• Left fallopian tube</li> <li>• Uterus</li> <li>• Cervix</li> <li>• Omentum</li> <li>• Peritoneal biopsies</li> <li>• Peritoneal washings/ascitic fluid</li> <li>• Lymph nodes</li> <li>• Other</li> </ul>	
Specimen type, Lymph nodes, specify	Free text	Only applicable if 'Specimen type, Lymph nodes' is selected.
Specimen type, Other, specify	Free text	Only applicable if 'Specimen type, Other' is selected.
Specimen integrity, Right ovary	Multiple selection value list: <ul style="list-style-type: none"> <li>• Ovarian capsule intact</li> <li>• Ovarian capsule ruptured</li> <li>• Tumour on surface</li> <li>• Fragmented specimen</li> <li>• Other</li> </ul>	Only applicable if 'Specimen type, Right ovary' or 'Specimen type, Right ovarian cystectomy' is selected.
Specimen integrity, Right ovary, Other	Free text	Only applicable if 'Specimen integrity, Right ovary, Other' is selected.
Specimen integrity, Left ovary	Multiple selection value list: <ul style="list-style-type: none"> <li>• Ovarian capsule intact</li> <li>• Ovarian capsule ruptured</li> <li>• Tumour on surface</li> <li>• Fragmented specimen</li> <li>• Other</li> </ul>	Only applicable if 'Specimen type, Left ovary' or 'Specimen type, Left ovarian cystectomy' is selected.
Specimen integrity, Left ovary, Other	Free text	Only applicable if 'Specimen integrity, Left ovary, Other' is selected.
Specimen integrity, Right fallopian tube	Multiple selection value list: <ul style="list-style-type: none"> <li>• Serosa intact</li> <li>• Serosa ruptured</li> <li>• Tumour on serosal</li> </ul>	Only applicable if 'Specimen type, Right fallopian tube' is selected.

	<p>surface</p> <ul style="list-style-type: none"> <li>• Fragmented specimen</li> <li>• Other</li> </ul>	
Specimen integrity, Right fallopian tube, Other	Free text	Only applicable if 'Specimen integrity, Right fallopian tube, Other' is selected.
Specimen integrity, Left fallopian tube	<p>Multiple selection value list:</p> <ul style="list-style-type: none"> <li>• Serosa intact</li> <li>• Serosa ruptured</li> <li>• Tumour on serosal surface</li> <li>• Fragmented specimen</li> <li>• Other</li> </ul>	Only applicable if 'Specimen type, Left fallopian tube' is selected.
Specimen integrity, Left fallopian tube, Other	Free text	Only applicable if 'Specimen integrity, Left fallopian tube, Other' is selected.
Macroscopic tumour site	<p>Multiple selection value list:</p> <ul style="list-style-type: none"> <li>• Right ovary</li> <li>• Right fallopian tube</li> <li>• Left ovary</li> <li>• Left fallopian tube</li> <li>• Omentum</li> <li>• Peritoneum</li> <li>• Other</li> <li>• Indeterminate</li> </ul>	
Macroscopic tumour site, Right fallopian tube	<p>Multiple selection value list:</p> <ul style="list-style-type: none"> <li>• Fimbrial</li> <li>• Non-fimbrial</li> </ul>	Only applicable if 'Macroscopic tumour site, Right fallopian tube' is selected.
Macroscopic tumour site, Left fallopian tube	<p>Multiple selection value list:</p> <ul style="list-style-type: none"> <li>• Fimbrial</li> <li>• Non-fimbrial</li> </ul>	Only applicable if 'Macroscopic tumour site, Left fallopian tube' is selected.
Macroscopic tumour site, Other	Free text	Only applicable if 'Macroscopic tumour site, Other' is selected.
Omentum dimension 1	Size in mm	
Omentum dimension 2	Size in mm	
Omentum dimension 3	Size in mm	
Omental involvement	<p>Single selection value list:</p> <ul style="list-style-type: none"> <li>• Involved</li> <li>• Not involved</li> </ul>	
Omentum, Maximum dimension of largest deposit	Size in mm	
Histological tumour type and grade	<p>Single selection value list:</p> <ul style="list-style-type: none"> <li>• Serous</li> <li>• Serous micropapillary</li> </ul>	

	<p>variant</p> <ul style="list-style-type: none"> <li>• Mucinous</li> <li>• Endometrioid</li> <li>• Clear cell</li> <li>• Mixed epithelial subtypes</li> <li>• Other</li> </ul>	
Histological tumour type and grade, Specify	Free text	Only applicable if 'Histological tumour type and grade, Mixed epithelial types' or 'Histological tumour type and grade, Other' is selected.
Non-invasive implants	<p>Single selection value list:</p> <ul style="list-style-type: none"> <li>• Not identified</li> <li>• Present, Epithelial</li> <li>• Present, Desmoplastic</li> </ul>	Only applicable if 'Histological tumour type and grade, Serous' or 'Histological tumour type and grade, Serous micropapillary variant' is selected.
Non-invasive implants, sites	<p>Multiple selection value list:</p> <ul style="list-style-type: none"> <li>• Pelvic</li> <li>• Abdominal</li> </ul>	Only applicable if 'Non-invasive implants, Present, Epithelial' or 'Non-invasive implants, Present, Desmoplastic' is selected.
Invasive implants/Extra-ovarian low-grade serous carcinoma	<p>Single selection value list:</p> <ul style="list-style-type: none"> <li>• Not identified</li> <li>• Present</li> </ul>	Only applicable if 'Histological tumour type and grade, Serous' or 'Histological tumour type and grade, Serous micropapillary variant' is selected.
Invasive implants/Extra-ovarian low-grade serous carcinoma, sites	<p>Multiple selection value list:</p> <ul style="list-style-type: none"> <li>• Pelvic</li> <li>• Abdominal</li> </ul>	Only applicable if 'Invasive implants/Extra-ovarian low-grade serous carcinoma, Present' is selected.
Indeterminate implants	<p>Single selection value list:</p> <ul style="list-style-type: none"> <li>• Not identified</li> <li>• Present</li> </ul>	Only applicable if 'Histological tumour type and grade, Serous' or 'Histological tumour type and grade, Serous micropapillary variant' is selected.
Indeterminate implants, sites	<p>Multiple selection value list:</p> <ul style="list-style-type: none"> <li>• Pelvic</li> <li>• Abdominal</li> </ul>	Only applicable if 'Indeterminate implants, Present' is selected.
Histological sites of tumour involvement, Right ovary	<p>Single selection value list:</p> <ul style="list-style-type: none"> <li>• Not involved</li> <li>• Involved</li> <li>• Cannot be assessed</li> <li>• Not applicable</li> </ul>	Not applicable if 'Specimen type' does not include 'Right ovary' or 'Right ovarian cystectomy'.
Histological sites of tumour	Single selection value list:	Not applicable if

involvement, Left ovary	<ul style="list-style-type: none"> <li>• Not involved</li> <li>• Involved</li> <li>• Cannot be assessed</li> <li>• Not applicable</li> </ul>	'Specimen type' does not include 'Left ovary' or 'Left ovarian cystectomy'.
Histological sites of tumour involvement, Right ovarian capsule/surface	Single selection value list: <ul style="list-style-type: none"> <li>• Not involved</li> <li>• Involved</li> <li>• Cannot be assessed</li> <li>• Not applicable</li> </ul>	Not applicable if 'Specimen type' does not include 'Right ovary' or 'Right ovarian cystectomy'.
Histological sites of tumour involvement, Left ovarian capsule/surface	Single selection value list: <ul style="list-style-type: none"> <li>• Not involved</li> <li>• Involved</li> <li>• Cannot be assessed</li> <li>• Not applicable</li> </ul>	Not applicable if 'Specimen type' does not include 'Left ovary' or 'Left ovarian cystectomy'.
Histological sites of tumour involvement, Right fallopian tube	Single selection value list: <ul style="list-style-type: none"> <li>• Not involved</li> <li>• Involved</li> <li>• Cannot be assessed</li> <li>• Not applicable</li> </ul>	Not applicable if 'Specimen type' does not include 'Right fallopian tube'.
Histological sites of tumour involvement, Left fallopian tube	Single selection value list: <ul style="list-style-type: none"> <li>• Not involved</li> <li>• Involved</li> <li>• Cannot be assessed</li> <li>• Not applicable</li> </ul>	Not applicable if 'Specimen type' does not include 'Left fallopian tube'.
Histological sites of tumour involvement, Uterus	Single selection value list: <ul style="list-style-type: none"> <li>• Not involved</li> <li>• Involved</li> <li>• Cannot be assessed</li> <li>• Not applicable</li> </ul>	Not applicable if 'Specimen type' does not include 'Uterus'.
Histological sites of tumour involvement, Uterus, Site(s)	Multiple selection value list: <ul style="list-style-type: none"> <li>• Myometrium</li> <li>• Endometrium</li> <li>• Cervix</li> </ul>	Only applicable if 'Histological sites of tumour involvement, Uterus, Involved' is selected.
Histological sites of tumour involvement, Omentum	Single selection value list: <ul style="list-style-type: none"> <li>• Not involved</li> <li>• Involved</li> <li>• Cannot be assessed</li> <li>• Not applicable</li> </ul>	Not applicable if 'Specimen type' does not include 'Omentum'.
Histological sites of tumour involvement, Omentum, Level of involvement	Single selection value list: <ul style="list-style-type: none"> <li>• Microscopic</li> <li>• Macroscopic</li> </ul>	Only applicable if 'Histological sites of tumour involvement, Omentum, Involved' is selected.
Histological sites of tumour involvement, Peritoneum (including uterine serosa)	Single selection value list: <ul style="list-style-type: none"> <li>• Not involved</li> <li>• Involved</li> <li>• Cannot be assessed</li> </ul>	Not applicable if 'Specimen type' does not include 'Peritoneal biopsies'.

	<ul style="list-style-type: none"> <li>• Not applicable</li> </ul>	
Histological sites of tumour involvement, Peritoneum (including uterine serosa), Site(s)	<p>Multiple selection value list:</p> <ul style="list-style-type: none"> <li>• Pelvis</li> <li>• Abdomen</li> </ul>	Only applicable if 'Histological sites of tumour involvement, Peritoneum (including uterine serosa), Involved' is selected.
Histological sites of tumour involvement, Peritoneum (including uterine serosa), Site(s), Pelvis, specify	Free text	Only applicable if 'Histological involvement, Peritoneum (including uterine serosa), Site(s), Pelvis' is selected.
Histological sites of tumour involvement, Peritoneum (including uterine serosa), Site(s), Abdomen, specify	Free text	Only applicable if 'Histological involvement, Peritoneum (including uterine serosa), Site(s), Abdomen' is selected.
Other involved organ(s)/site(s)	Free text	
Peritoneal cytology	<p>Single selection value list:</p> <ul style="list-style-type: none"> <li>• Negative</li> <li>• Positive</li> <li>• Indeterminate</li> <li>• Not received</li> </ul>	
Lymph node status	<p>Single selection value list:</p> <ul style="list-style-type: none"> <li>• Not submitted</li> <li>• Not involved</li> <li>• Involved</li> </ul>	
Regional lymph nodes, Left pelvic, Number of lymph nodes examined	Integer	Not applicable if 'Lymph node status, Not submitted' is selected.
Regional lymph nodes, Left pelvic, Number of positive lymph nodes	Integer	Not applicable if 'Lymph node status, Not submitted' is selected or 'Regional lymph nodes, Left pelvic, Number of lymph nodes examined' is <1.
Regional lymph nodes, Right pelvic, Number of lymph nodes examined	Integer	Not applicable if 'Lymph node status, Not submitted' is selected.
Regional lymph nodes, Right pelvic, Number of positive lymph nodes	Integer	Not applicable if 'Lymph node status, Not submitted' is selected or 'Regional lymph nodes, Right pelvic, Number of lymph nodes examined' is <1.
Regional lymph nodes, Para-aortic, Number of lymph nodes examined	Integer	Not applicable if 'Lymph node status, Not submitted' is selected.
Regional lymph nodes, Para-aortic, Number of positive lymph nodes	Integer	Not applicable if 'Lymph node status, Not submitted' is selected or 'Regional lymph nodes,

		Para-aortic, Number of lymph nodes examined' is <1.
Non-regional lymph node, Site 1	Free text	Not applicable if 'Lymph node status, Not submitted' is selected.
Non-regional lymph nodes, Site 1, Number of lymph nodes examined	Integer	Not applicable if 'Lymph node status, Not submitted' is selected.
Non-regional lymph nodes, Site 1, Number of positive lymph nodes	Integer	Not applicable if 'Lymph node status, Not submitted' is selected or 'Non-regional lymph nodes, Site 1, Number of lymph nodes examined' is <1.
Non-regional lymph node, Site 2	Free text	Not applicable if 'Lymph node status, Not submitted' is selected.
Non-regional lymph nodes, Site 2, Number of lymph nodes examined	Integer	Not applicable if 'Lymph node status, Not submitted' is selected.
Non-regional lymph nodes, Site 2, Number of positive lymph nodes	Integer	Not applicable if 'Lymph node status, Not submitted' is selected or 'Non-regional lymph nodes, Site 2, Number of lymph nodes examined' is <1.
Site of tumour	Single selection value list: <ul style="list-style-type: none"> <li>• Primary tumour, ovary</li> <li>• Primary tumour, fallopian tube</li> <li>• Primary tumour, peritoneum</li> <li>• Undesignated: site of primary tumour cannot be assessed</li> </ul>	
Comments	Free text	
Provisional FIGO stage	Single selection value list: <ul style="list-style-type: none"> <li>• IA</li> <li>• IB</li> <li>• IC1</li> <li>• IC2</li> <li>• IC3</li> <li>• IIA</li> <li>• IIB</li> <li>• IIIA1i</li> <li>• IIIA1ii</li> <li>• IIIA2</li> </ul>	

	<ul style="list-style-type: none"> <li>• IIIB</li> <li>• IIIC</li> <li>• IVA</li> <li>• IVB</li> </ul>	
SNOMED T code	May have multiple codes. Look up from SNOMED tables.	
SNOMED M code	May have multiple codes. Look up from SNOMED tables.	



## Appendix H Summary table – explanation of grades of evidence

(modified from Palmer K *et al. BMJ* 2008;337:1832)

Grade (level) of evidence	Nature of evidence
Grade A	At least one high-quality meta-analysis, systematic review of randomised controlled trials or a randomised controlled trial with a very low risk of bias and directly attributable to the target cancer type or A body of evidence demonstrating consistency of results and comprising mainly well-conducted meta-analyses, systematic reviews of randomised controlled trials or randomised controlled trials with a low risk of bias, directly applicable to the target cancer type.
Grade B	A body of evidence demonstrating consistency of results and comprising mainly high-quality systematic reviews of case-control or cohort studies and high-quality case-control or cohort studies with a very low risk of confounding or bias and a high probability that the relation is causal and which are directly applicable to the target cancer type or Extrapolation evidence from studies described in A.
Grade C	A body of evidence demonstrating consistency of results and including well-conducted case-control or cohort studies and high-quality case-control or cohort studies with a low risk of confounding or bias and a moderate probability that the relation is causal and which are directly applicable to the target cancer type or Extrapolation evidence from studies described in B.
Grade D	Non-analytic studies such as case reports, case series or expert opinion or Extrapolation evidence from studies described in C.
Good practice point (GPP)	Recommended best practice based on the clinical experience of the authors of the writing group.

## Appendix I      AGREE II guideline monitoring sheet

The cancer datasets of the Royal College of Pathologists comply with the AGREE II standards for good quality clinical guidelines. The sections of this dataset that indicate compliance with each of the AGREE II standards are indicated in the table.

<b>AGREE standard</b>	<b>Section of guideline</b>
<b>Scope and purpose</b>	
1 The overall objective(s) of the guideline is (are) specifically described	Introduction
2 The health question(s) covered by the guideline is (are) specifically described	Introduction
3 The population (patients, public, etc.) to whom the guideline is meant to apply is specifically described	Foreword
<b>Stakeholder involvement</b>	
4 The guideline development group includes individuals from all the relevant professional groups	Foreword
5 The views and preferences of the target population (patients, public, etc.) have been sought	Foreword
6 The target users of the guideline are clearly defined	Introduction
<b>Rigour of development</b>	
7 Systematic methods were used to search for evidence	Foreword
8 The criteria for selecting the evidence are clearly described	Foreword
9 The strengths and limitations of the body of evidence are clearly described	Foreword
10 The methods for formulating the recommendations are clearly described	Foreword
11 The health benefits, side effects and risks have been considered in formulating the recommendations	Foreword and Introduction
12 There is an explicit link between the recommendations and the supporting evidence	2–8
13 The guideline has been externally reviewed by experts prior to its publication	Foreword
14 A procedure for updating the guideline is provided	Foreword
<b>Clarity of presentation</b>	
15 The recommendations are specific and unambiguous	2–8
16 The different options for management of the condition or health issue are clearly presented	2–8
17 Key recommendations are easily identifiable	2–8
<b>Applicability</b>	
18 The guideline describes facilitators and barriers to its application	Foreword
19 The guideline provides advice and/or tools on how the recommendations can be put into practice	Appendices
20 The potential resource implications of applying the recommendations have been considered	Foreword
21 The guideline presents monitoring and/or auditing criteria	9
<b>Editorial independence</b>	
22 The views of the funding body have not influenced the content of the guideline	Foreword
23 Competing interests of guideline development group members have been recorded and addressed	Foreword