



The Royal College of **Pathologists**

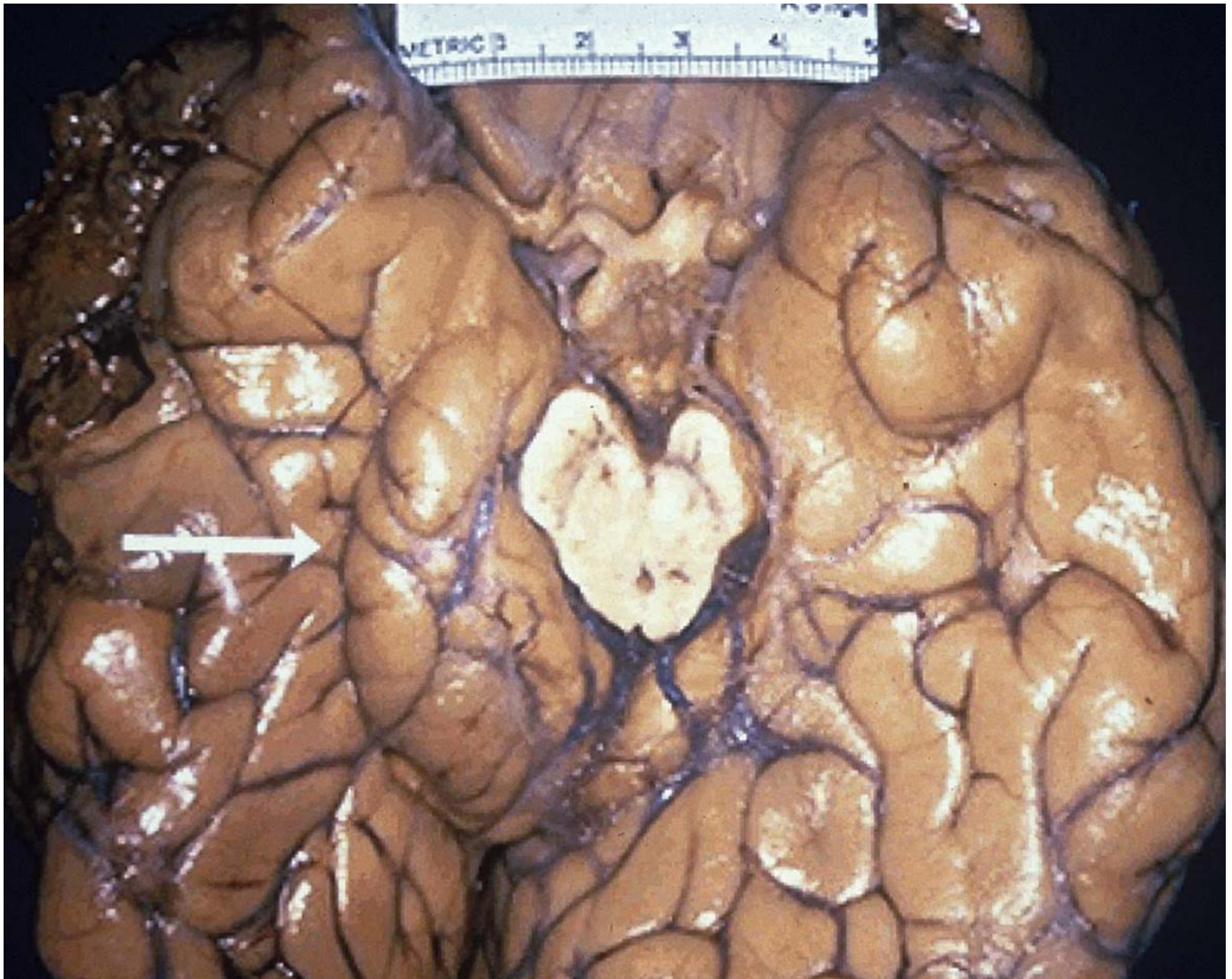Pathology: the science behind the cure

FRCPath Part 1 in Histopathology

Sample MCQ and EMQs



1. A 17 year old man was injured in a road traffic accident. He died shortly after admission.

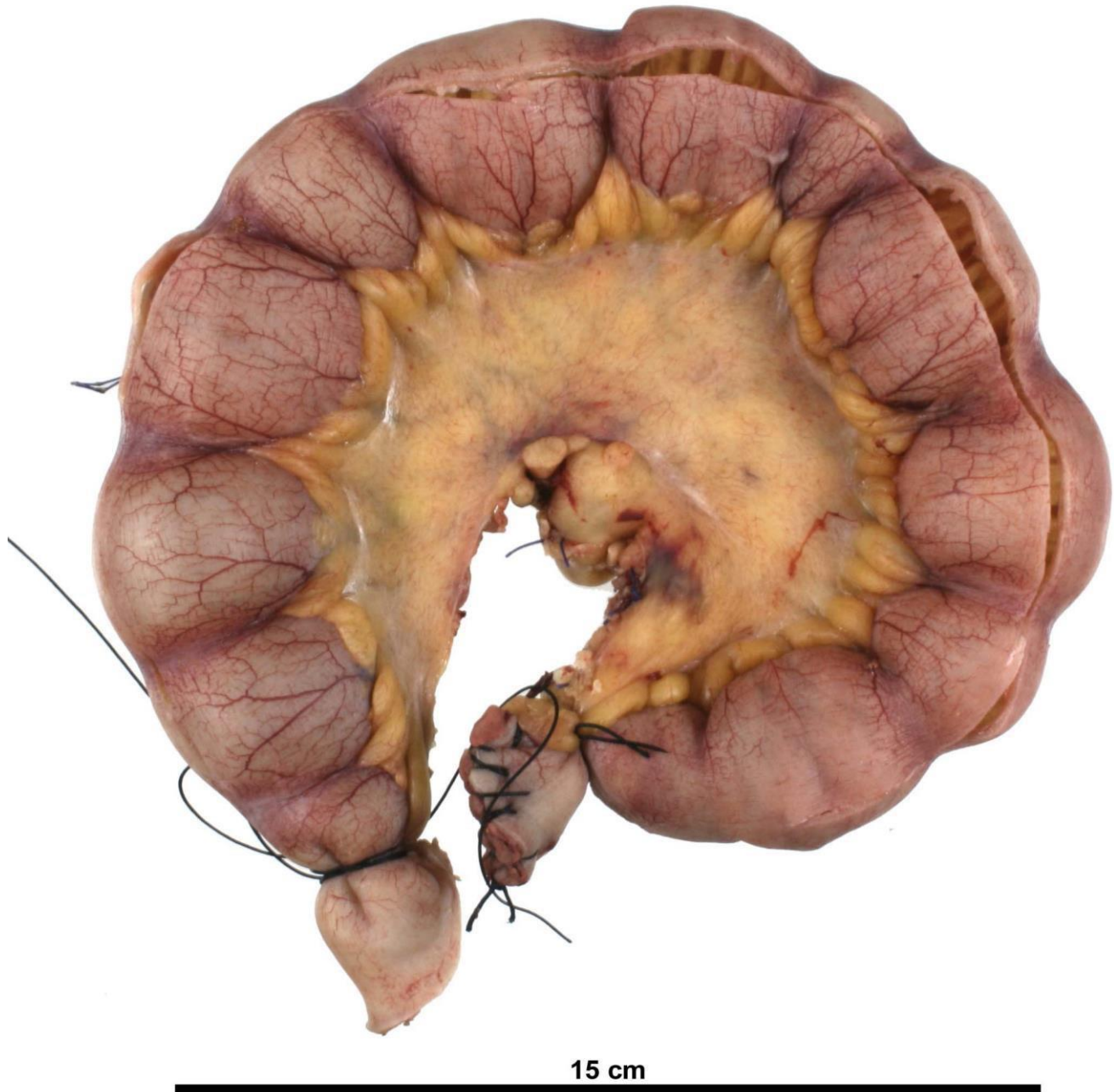


What part of the brain does the arrow indicate?

- A) Cerebellar peduncle
- B) Cerebellar vermis
- C) Cingulate gyrus
- D) Corpus callosum
- E) Parahippocampal gyrus



2. A 65 year old man with a background of longstanding osteoarthritis has had recurrent episodes of cramping abdominal pain before presenting with obstruction. At laparotomy, a piece of abnormal small bowel is resected and sent for pathological examination. Below is an image of this bowel:

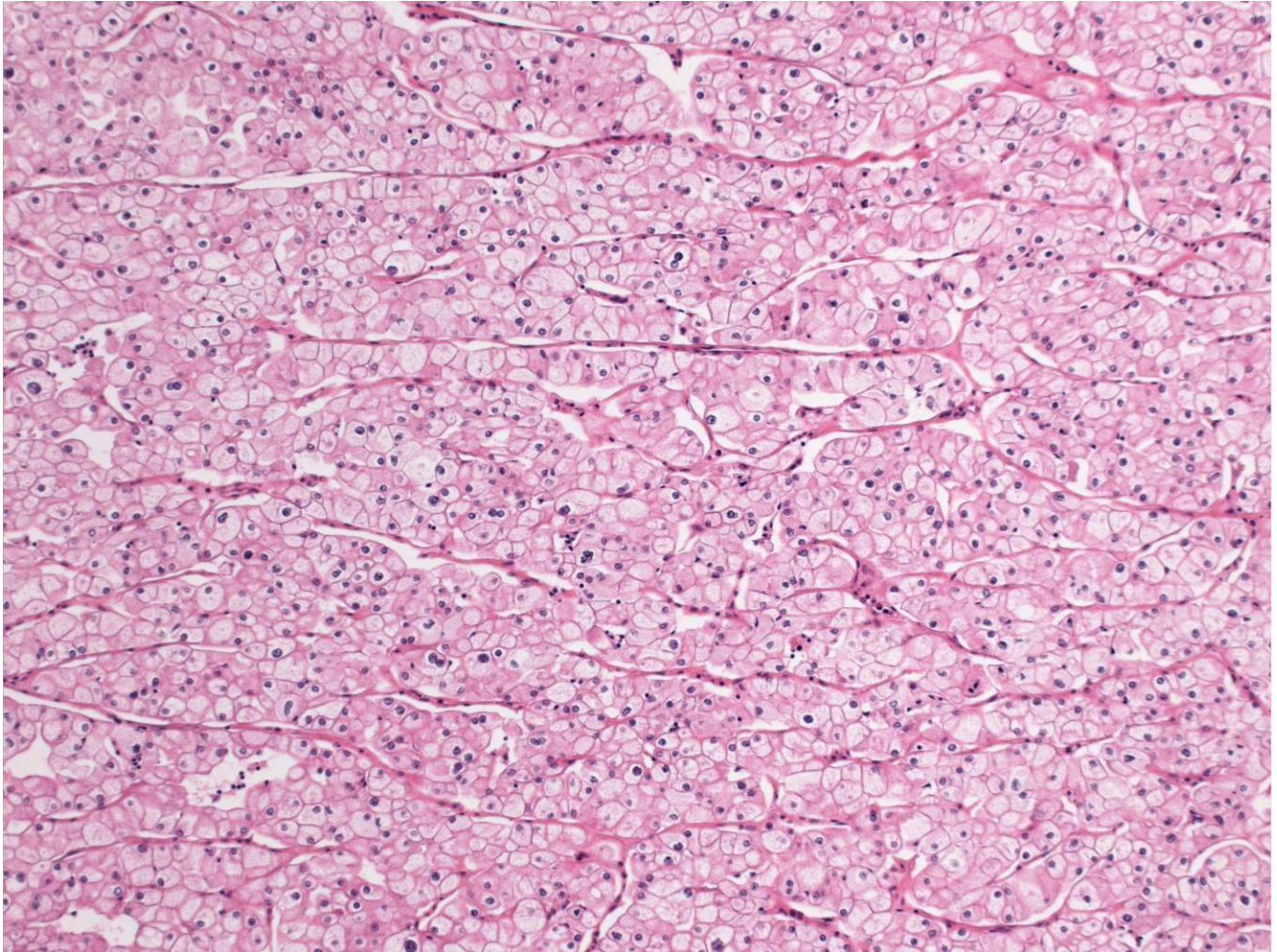


Which of the following options is the most likely diagnosis?

- A) Crohn's disease
- B) Diaphragm disease (NSAID induced strictures)
- C) Malignant Lymphoma
- D) Mesenteric Ischaemia
- E) Tuberculosis



3. A 57-year-old man presented with visible haematuria and following imaging a renal neoplasm was diagnosed. The patient has a history of recurrent spontaneous pneumothorax and skin lesions. A radical nephrectomy was performed and a representative photomicrograph of the tumour is shown.



Which of the following familial cancer syndromes do you suspect this patient may have inherited?

- A) Birt-Hogg-Dubé syndrome
- B) Hereditary leiomyomatosis and renal cancer syndrome
- C) Hereditary papillary renal carcinoma syndrome
- D) Tuberous Sclerosis syndrome
- E) Von Hippel-Lindau syndrome



A 75 year old retired dockyard plumber presents with breathlessness and weight loss. A chest X-ray reveals an unilateral pleural effusion. Cytological examination of a sample of the effusion identifies cellular epithelioid clusters with “intercellular windows” and collagenous cores.

Identify the most likely diagnosis.

Option list

- A Bronchogenic squamous cell carcinoma
- B Malignant melanoma
- C Malignant mesothelioma
- D Metastatic prostatic carcinoma
- E Non-Hodgkin’s lymphoma

A 70 year old retired carpenter presents with recurrent nose bleeds. Rhinoscopy reveals an exophytic granular turbinate mass.

Select the most likely diagnosis.

Option list

- A Benign fibro-osseous lesion
- B Malignant Non-Hodgkin’s lymphoma
- C Nasal adenocarcinoma
- D Olfactory neuroblastoma
- E Pleomorphic adenoma

A fine needle aspirate (FNA) of the thyroid gland has suggested a diagnosis of papillary carcinoma, and the thyroid gland is resected surgically.

Identify the most important aspect of the macroscopical examination and cut-up.

Option list

- A Measuring the size of the tumour measured in three dimensions
- B Painting the two lobes of the gland with different colour inks
- C Taking a block to include the tumour and the nearest surgical margin
- D Taking a block of the apparently normal part of the gland
- E Weighing the gland



The Royal College of Pathologists

Pathology: the science behind the cure

A 62 year old man, known to suffer from alcohol abuse, was found dead in bed. At the Coroner's post mortem examination, you note that both lungs are heavy, oedematous and appear consolidated. Microscopically, you see a giant cell reaction to foreign material, and adjacent areas show acute inflammation in alveolar spaces.

Identify the most likely diagnosis.

Option list

- A Adult respiratory distress syndrome
- B Aspiration pneumonia
- C Klebsiella pneumonia
- D Pulmonary infarction
- E Pulmonary tuberculosis



Option List

- A Colloid cyst
- B Follicular adenoma
- C Follicular carcinoma
- D Follicular variant of papillary carcinoma
- E Graves' disease
- F Hashimoto's thyroiditis
- G Malignant lymphoma
- H Medullary carcinoma
- I Metastatic malignant melanoma
- J Nodular lymphoma
- K Oncocytic adenoma
- L Classical papillary carcinoma
- M Thyroid atrophy
- N Undifferentiated (anaplastic) carcinoma

In each of the following case histories the patients have some form of thyroid disease. For each one, select the most likely diagnosis from the list of options. Each option may be used once, more than once, or not at all.

- 1 A 43 year old woman has a thyroid lobe removed. It is seen to have a nodular architecture and a lymphoid infiltrate with multifocal Hürthle (oncocytic) change of follicular cells. The lymphocytes are positive for CD20 and CD79a and negative for CD3.

Answer: Hashimoto's thyroiditis

- 2 A 40 year old man has an isotope scan of his thyroid gland, which shows a "cold" nodule. This nodule is removed and, histologically, it is found to be composed of small follicular structures, with normal appearing nuclei, surrounded by an intact fibrous capsule; there is no evidence of vascular penetration.

Answer: Follicular adenoma

- 3 A 38 year old woman has an isotope scan of her thyroid gland which shows a "cold" nodule. This nodule is removed and, histologically, it is found to have a follicular architecture with prominent cleaving and grooving of nuclei. There are some irregular fibrotic bands, but no definite capsule.

Answer: Follicular variant of papillary carcinoma

- 4 An 89 year old female presents with stridor. A CT scan of her neck shows extensive infiltration of her trachea by a lesion arising from the thyroid gland. Fine needle aspiration of the gland shows cohesive clumps of cells.

Answer: Undifferentiated (anaplastic) carcinoma

- 5 A 35 year old woman has a thyroidectomy for an abnormal mass. Histologically, there is a tumour that contains areas of eosinophilic and congophilic acellular material.

Answer: Medullary carcinoma



Option List

- A Alcian blue/PAS
- B CAM 5.2
- C CD45
- D Chloracetate esterase
- E GFAP
- F HMB45
- G Modified Giemsa
- H PAS with diastase
- I Perls
- J Smooth muscle myosin
- K Ziehl-Neelsen

In each of the following situations, select the special stain most likely to help make a definitive diagnosis from the list of options. Each option may be used once, more than once, or not at all.

- 1 A 45 year old male presents with dyspepsia. A gastric biopsy shows a lymphoid infiltrate with occasional follicular centres in the lamina propria, with occasional neutrophils in the foveolar epithelium.

Answer: Modified Giemsa

- 2 A 30 year old female undergoes a cervical lymph node biopsy. Large aggregates of histiocytes with multinucleate giant cells are present, and several show areas of central necrosis.

Answer: Ziehl-Neelsen

- 3 A 75 year old female undergoes biopsy of a painful erythematous area on the tongue. The biopsy shows epithelial hyperplasia with collections of neutrophil polymorphs in superficial epithelial layers.

Answer: PAS + diastase

- 4 A 10 year old male presents with an urticarial rash that has faded to leave flat pigmented areas. A biopsy shows melanin in the superficial dermis, with large numbers of cells with granular cytoplasm, aggregated around dermal capillaries.

Answer: Chloracetate esterase

- 10 A 55 year old female with a history of breast cancer presents with increasing proptosis and a frozen right orbit. An orbital biopsy shows fibrotic tissue containing clusters and cords of hyperchromatic cells.

Answer: CAM 5.2